
PATIENT PRESENTING CLINICAL SIGNS

Bear Flynn Diarrhea for two weeks suspect intestinal mass found on ultrasound

COMPUTED TOMOGRAPHIC STUDY OF THE THORAX AND ABDOMEN
SPECIES

A high resolution pre- and post-contrast CT study of the thorax and abdomen is provided for review.

Canine

COMPUTED TOMOGRAPHIC FINDINGS
BREED
Thorax

The bony and surrounding soft tissue structures are within normal limits.

Golden Retriever

The sternal lymph nodes are enlarged and rounded.

SEX

The cardiovascular structures including the pulmonary vasculature are within normal limits.

Neutered Male

The bronchial tree presents with regular branching and tapers uniformly towards the periphery as expected, the bronchial walls are thin and smooth. The bronchus-to-artery ratio is within normal limits.

AGE

The lung parenchyma presents the expected architecture and attenuation behavior, but zone with dystelectasis of the dorsal dependent aspects of the left caudal lung lobe.

10

Small incidental gas pockets are seen within the esophageal lumen, there is no evidence of abnormal dilation.

INTERPRETED BY
Abdomen

In the post contrast study, streak artefacts are present in the cranial and caudal abdomen.

Sebastian Schaub,
 DVM Dr. med. vet.
 DipECVDI

A small volume of fluid attenuating material is visible in peritoneal cavity. Accentuated in the cranial abdomen, the peritoneal fat presents a diffuse net like arrangement of soft tissue attenuating and mild contrast enhancing nodules.

HOSPITAL NAME

Scottsdale Vet Clinic

Both kidneys present within normal limits for size, shape and organ architecture. After contrast administration a bilaterally symmetric and uniform nephro- and pyelogram is noted.

The adrenal glands are within normal limits for size, shape and organ architecture.

REFERRING VET

Dr. Kerby

Both liver and spleen present with normal shape, even surface, uniformly attenuating parenchyma and homogeneous contrast enhancement, unremarkable.

INVOICE

44380

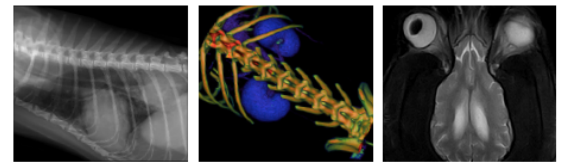
A small intestinal segment in the mid abdomen presents a circumferential thickened wall, measuring up to 3.1 cm in width; the affected intestinal segment is measuring approximately 9 cm in length. The wall layering of the affected small intestinal segment is lost.

An enlarged and rounded jejunal lymph node is appreciated.

DATE

7/27/23

Multifocal mild spondylosis formation is seen along the lumbar spine.



PATIENT COMPUTED TOMOGRAPHIC DIAGNOSIS

Bear Flynn

- Segmental small intestinal mural mass
- Multiple soft tissue nodules throughout the peritoneal cavity
- Lymphadenopathy jejunal lymph node and sternal lymph nodes

SPECIES

Canine

- Mild peritoneal effusion
- Spondylosis deformans
- No evidence of pulmonary metastatic disease

BREED

Golden Retriever

INTERPRETATION OF THE FINDINGS & FURTHER RECOMMENDATIONS

The CT study is confirming the diagnosis of a small intestinal mural neoplastic mass – differentials include adenocarcinoma, leiomyosarcoma, gastrointestinal stromal cell tumor, round cell tumor. Given the peritoneal nodules, the odds for carcinomatosis and metastatic spread to the tributary lymph nodes are high.

SEX

Neutered Male

AGE

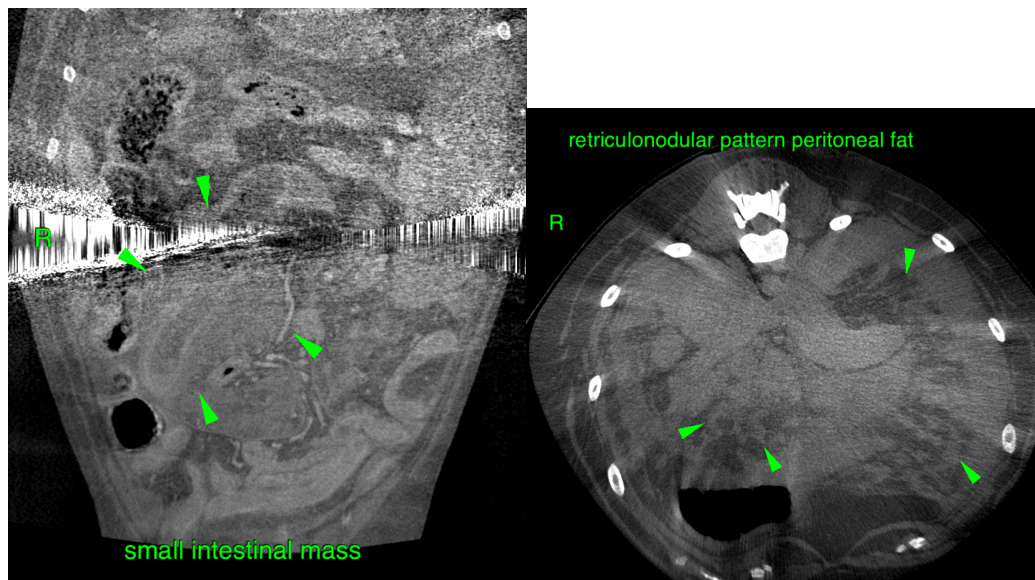
10

INTERPRETED BY

Sebastian Schaub,
DVM Dr. med. vet.
DipECVDI

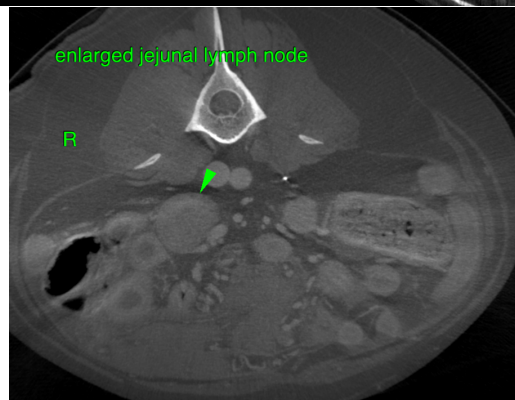
HOSPITAL NAME

Scottsdale Vet Clinic



REFERRING VET

Dr. Kerby

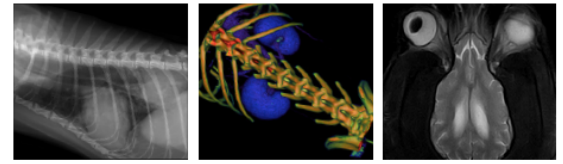


INVOICE

44380

DATE

7/27/23



PATIENT

The information and recommendations provided are based on the images presented by the referring veterinarian. No evaluation can be communicated regarding pathology that was not visible in the image/video clips provided.

Bear Flynn

SPECIES

Thank you for this referral. If the clinical or image interpretation does not parallel your findings or if I can be of any further assistance please contact me.

Canine

Sebastian Schaub, Sebastian Schaub, DVM, Dr. med. vet. DipECVDI
sebast.schaub@gmail.com

BREED

Golden Retriever

SEX

Neutered Male

AGE

10

INTERPRETED BY

Sebastian Schaub,
DVM Dr. med. vet.
DipECVDI

HOSPITAL NAME

Scottsdale Vet Clinic

REFERRING VET

Dr. Kerby

INVOICE

44380

DATE

7/27/23