



PATIENT

Ziggy Stardust
Cochran

PRESENTING CLINICAL SIGNS

CT scan looking for retained testicle - pet was a bilateral cryptorchid that had a neuter/exploratory performed twice (once in January 2022, 1 testicle found and removed, explored again March 2022 and no second testicle was found). Pet still has spines present on penis.

SPECIES

Feline

COMPUTED TOMOGRAPHY OF THE ABDOMEN

A high resolution pre- and post-contrast CT study of the abdomen is provided for review.

BREED

DSH

COMPUTED TOMOGRAPHIC FINDINGS

The serosal fat presents normal attenuation behavior. There is no evidence of peritoneal effusion or peritonitis.

SEX

Male

Both kidneys present within normal limits for size, shape and organ architecture. After contrast administration a bilaterally symmetric and uniform nephro- and pyelogram is noted.

The adrenal glands are within normal limits for size, shape and organ architecture.

Both liver and spleen present with normal shape, even surface, uniformly attenuating parenchyma and homogeneous contrast enhancement, unremarkable.

AGE

20 Months

The portal vein presents a normal order of its tributary veins and intrahepatic branching. No abnormal vessel is noted inside and outside of the liver parenchyma.

INTERPRETED BY

Sebastian Schaub, DVM
Dr. med. vet. DipECVDI

The pancreas is evenly contoured, the pancreatic parenchyma is homogeneous and presents uniform contrast enhancement.

The position, delineation, wall and content of the gastrointestinal tract are considered within normal limits throughout.

HOSPITAL NAME

Wilson Veterinary
Hospital

In the midline, the ventral abdominal wall is mildly heterogeneous with mild irregular contrast enhancement.

The right testicle is seen in the subcutaneous tissue of the right inguinal region – approximately level with the right obturator foramen – measuring 9 x 6 x 15 mm.

The left testicle is absent.

REFERRING VET

Dr. Barkham

COMPUTED TOMOGRAPHIC DIAGNOSIS

- Right sided inguinal cryptorchism
- History of celiotomy

INVOICE

53133

INTERPRETATION OF THE FINDINGS & FURTHER RECOMMENDATIONS

The right testicle is seen in right inguinal region, ventral to the right obturator foramen.

DATE

7-27-22



PATIENT

Ziggy Stardust
Cochran

SPECIES

Feline

BREED

DSH

SEX

Male

AGE

20 Months

INTERPRETED BY

Sebastian Schaub, DVM
Dr. med. vet. DipECVDI

HOSPITAL NAME

Wilson Veterinary
Hospital

REFERRING VET

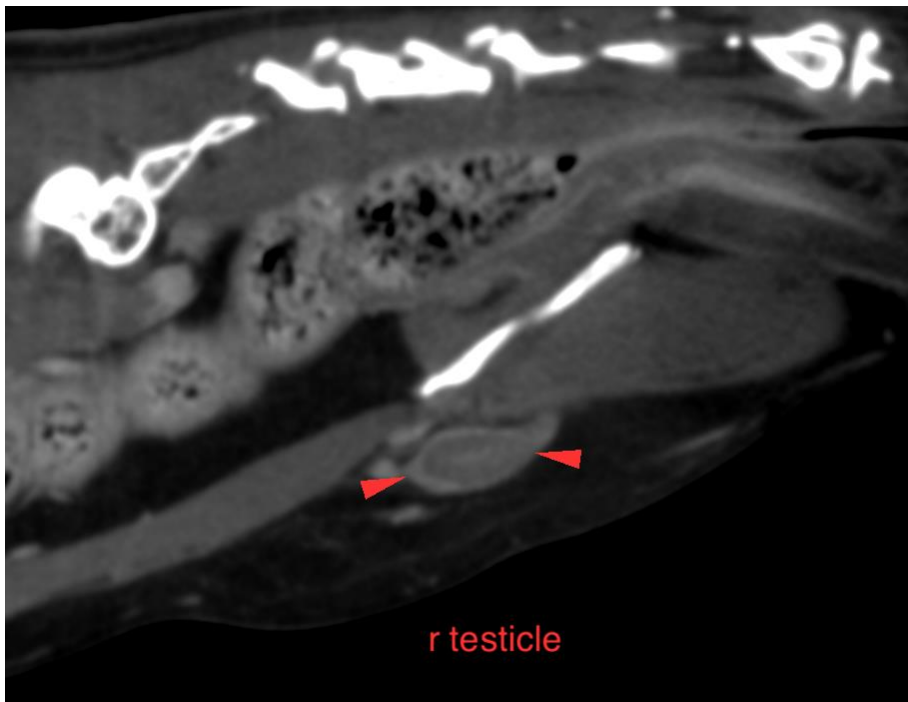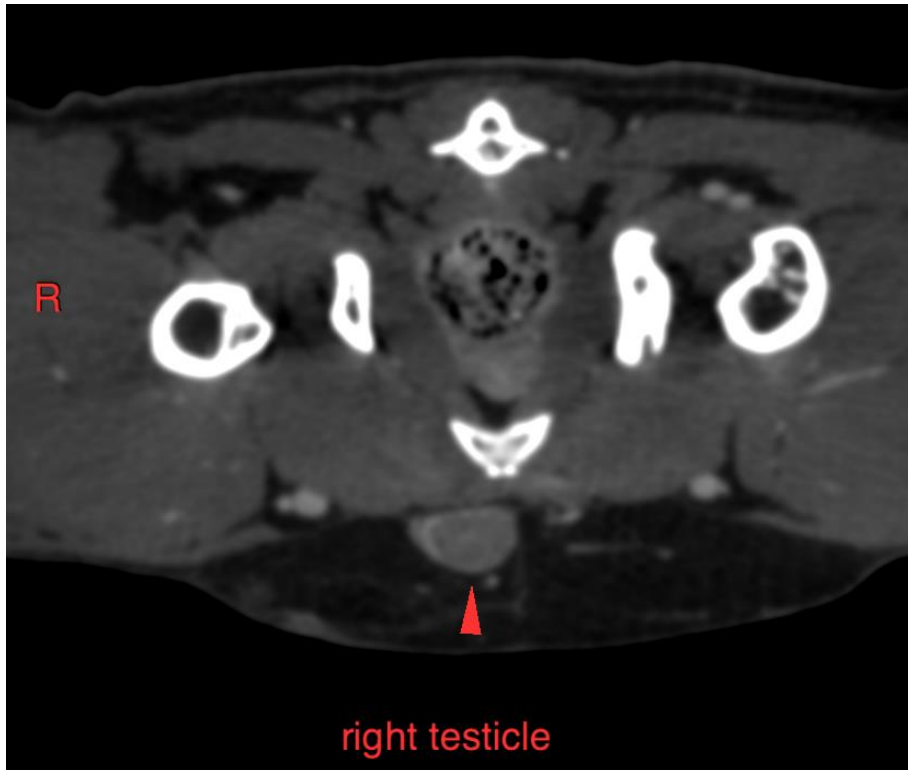
Dr. Barkham

INVOICE

53133

DATE

7-27-22





PATIENT

Ziggy Stardust
Cochran

The information and recommendations provided are based on the images presented by the referring veterinarian/sonographer. No evaluation can be communicated regarding pathology that was not visible in the image/video clips provided.

SPECIES

Feline

Thank you for this referral. If the clinical or image interpretation does not parallel your findings or if I can be of any further assistance please contact me.

BREED

DSH

Sebastian Schaub, Sebastian Schaub, DVM, Dr. med. vet. DipECVDI
sebast.schaub@gmail.com

SEX

Male

AGE

20 Months

INTERPRETED BY

Sebastian Schaub, DVM
Dr. med. vet. DipECVDI

HOSPITAL NAME

Wilson Veterinary
Hospital

REFERRING VET

Dr. Barkham

INVOICE

53133

DATE

7-27-22