



PATIENT PRESENTING CLINICAL SIGNS

Trixie Swartzman Sneezing and painful swelling proximal aspect muzzle/bridge of nose.

COMPUTED TOMOGRAPHY OF THE SKULL & THORAX

SPECIES A high resolution pre- and post-contrast CT study of the skull and a post-contrast CT study of the thorax are provided for review.

Canine

COMPUTED TOMOGRAPHIC FINDINGS

Skull

BREED The dentition is complete.
Poodle Mix

SEX Centered on the rostral third of the left nasal cavity, a uniform soft tissue attenuating and mild heterogeneous contrast enhancing mass is seen. The mass is perforating the nasal septum at the same level and the associated left maxillary bone, left palatine bone and nasal bone bilaterally present advanced aggressive osteolysis. The roots of the dental elements 203-207 are embedded within the mass.

FS

Both temporomandibular joints present congruent joint spaces with even subchondral bone surfaces and are considered within normal limits.

AGE

12 Years Both tympanic bullae are aerated, the mucosal lining is not seen, the bony wall is smooth and thin. The external ear canals are within normal limits.

INTERPRETED BY

Sebastian Schaub, DVM
Dr. med. vet. DipECVDI

The brain presents no deviation from normal anatomy and symmetry. The brain parenchyma is homogeneous and within normal limits for attenuation and distribution of contrast enhancement. The ventricular system is non-dilated and symmetric.

The left mandibular lymph nodes are mildly prominent.

Thorax

HOSPITAL NAME

Mobile Pet Imaging
CFL

The caudal cervical segment of the trachea is mildly dorsoventrally flattened, and the endotracheal tube is seen at the same level in the tracheal lumen.

The sternal, cranial mediastinal and tracheobronchial lymph nodes are small elongated with a normal short-to-long-axis-ratio is < 0.5, the attenuation and contrast enhancement pattern is uniform and considered within normal limits.

REFERRING VET

Borecky

The cardiovascular structures including the pulmonary vasculature are within normal limits.

The bronchial tree presents with regular branching and tapers uniformly towards the periphery as expected, the bronchial walls are thin and smooth. The bronchus-to-artery ratio is within normal limits.

INVOICE

53124

The lung parenchyma presents the expected architecture and attenuation behavior.

Small incidental gas pockets are seen within the esophageal lumen, there is no evidence of abnormal dilation.

DATE

7-27-22


PATIENT COMPUTED TOMOGRAPHIC DIAGNOSIS

Trixie Swartzman

- Biologically aggressive left sided nasal soft tissue neoplasia with polyostotic aggressive osteolytic lesions of the associated osseous structures
- Mild lymphadenopathy left mandibular lymph nodes
- Structural normal thorax, no evidence of pulmonary metastatic disease

SPECIES

Canine

INTERPRETATION OF THE FINDINGS & FURTHER RECOMMENDATIONS
BREED

Poodle Mix

The findings are consistent with a biologically aggressive soft tissue neoplasia, originating from the rostral aspect of the left nasal cavity with extensive osteolytic lesions of the associated osseous structures – extending up to the level of triadan 207. Differentials include adenocarcinoma, squamous cell carcinoma, transitional cell carcinoma, lymphosarcoma, other. FNA sampling can be used as advanced diagnostic tests. Based on the results of the advanced diagnostic tests, the chances of radiation therapy can be discussed with oncologist. The Adam tumor stage is T3.

SEX

For full tumor staging , recommend FNA sampling of the mild prominent left mandibular lymph nodes.

FS

AGE

12 Years

INTERPRETED BY

 Sebastian Schaub, DVM
 Dr. med. vet. DipECVDI

HOSPITAL NAME

 Mobile Pet Imaging
 CFL

REFERRING VET

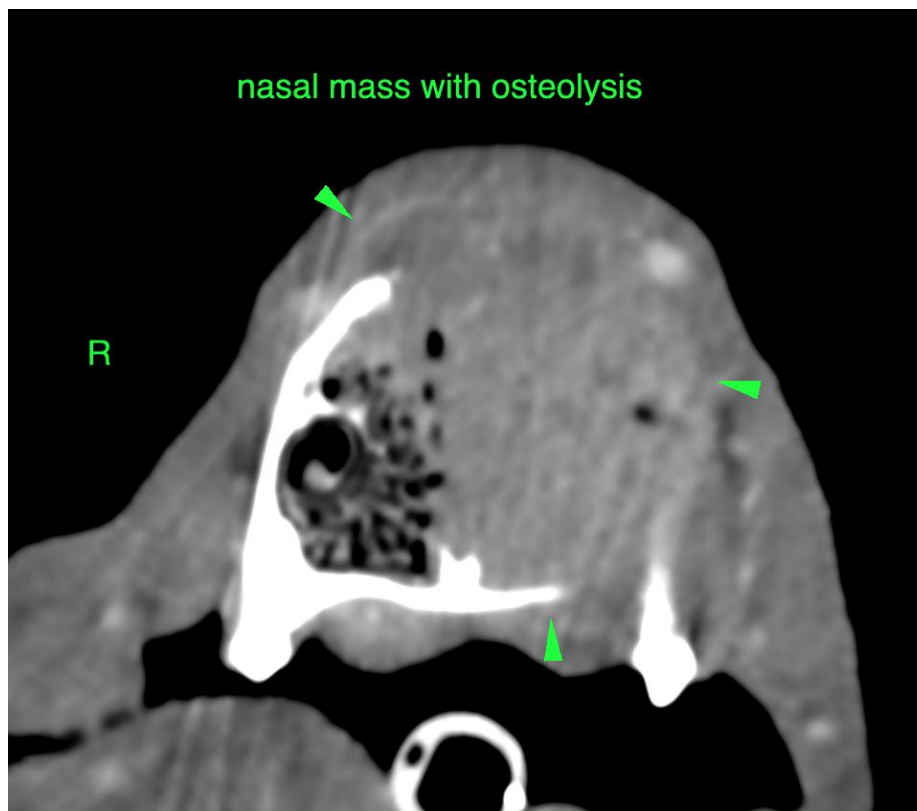
Borecky

INVOICE

53124

DATE

7-27-22





PATIENT

Trixie Swartzman

SPECIES

Canine

BREED

Poodle Mix

SEX

FS

AGE

12 Years

INTERPRETED BY

Sebastian Schaub, DVM
Dr. med. vet. DipECVDI

HOSPITAL NAME

Mobile Pet Imaging
CFL

REFERRING VET

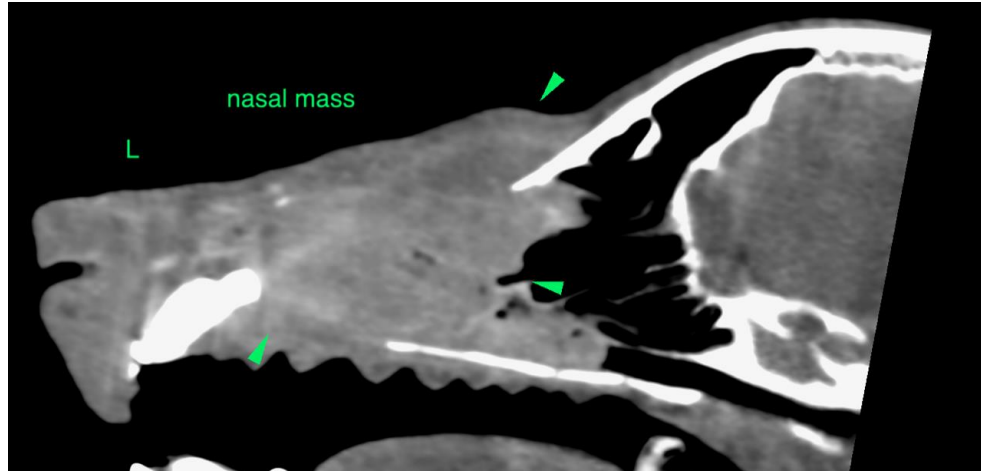
Borecky

INVOICE

53124

DATE

7-27-22



The information and recommendations provided are based on the images presented by the referring veterinarian/sonographer. No evaluation can be communicated regarding pathology that was not visible in the image/video clips provided.

Thank you for this referral. If the clinical or image interpretation does not parallel your findings or if I can be of any further assistance please contact me.

Sebastian Schaub, Sebastian Schaub, DVM, Dr. med. vet. DipECVDI
sebast.schaub@gmail.com