



PATIENT

Tess Shumaker

PRESENTING CLINICAL SIGNS

Limping left front side, fell off porch about 4 feet last year limping L front x 1.5 years per o. Limp will worsen with activity. Unable to elicit pain with palpation of either front limb. No lameness noted during exam_ *possible changes in Right elbow, and abnormal bony lesion noted distal R radius

SPECIES

Canine

RADIOGRAPHIC STUDY OF THE ELBOW JOINTS

Radiographs of the elbow joints in two orthogonal imaging planes are provided for review.

BREED

Lab Mix

RADIOGRAPHIC FINDINGS

The periarticular bones of both elbow joints present mild to moderate osteophyte new bone formation, R>L.

SEX

FS

Mild to moderate sclerosis at the base of the medial coronoid process is seen. The tip of the contour of the medial coronoid process is mildly ill-defined bilaterally, R>L.

A triangular shaped well-defined, solid mineralized osseous spur is protruding from the caudal cortex of the distal diaphysis of the radius.

AGE

6 Years, 3 Months

- Suspect coronoid disease elbow joints bilaterally
- Degenerative osteoarthritis elbow joints bilaterally, R>L
- Exostosis caudal aspect right distal diaphysis of the radius

INTERPRETED BY

Sebastian Schaub, DVM
Dr. med. vet. DipECVDI

INTERPRETATION OF THE FINDINGS & FURTHER RECOMMENDATIONS

The degenerative osteoarthritis of both elbow joints is very likely a sequela to disease of the medial coronoid process and a plausible explanation for the front limb lameness. A CT study of the elbow joints can be considered for further definition.

HOSPITAL NAME

Reid Veterinary
Hospital

The exostosis at the caudal aspect of the right radius is commonly an incidental finding.

REFERRING VET

Dr. Diane Heider

INVOICE

53134

DATE

7-27-22



PATIENT

Tess Shumaker

SPECIES

Canine

BREED

Lab Mix

SEX

FS

AGE

6 Years, 3 Months

INTERPRETED BY

Sebastian Schaub, DVM
Dr. med. vet. DipECVDI

HOSPITAL NAME

Reid Veterinary
Hospital

REFERRING VET

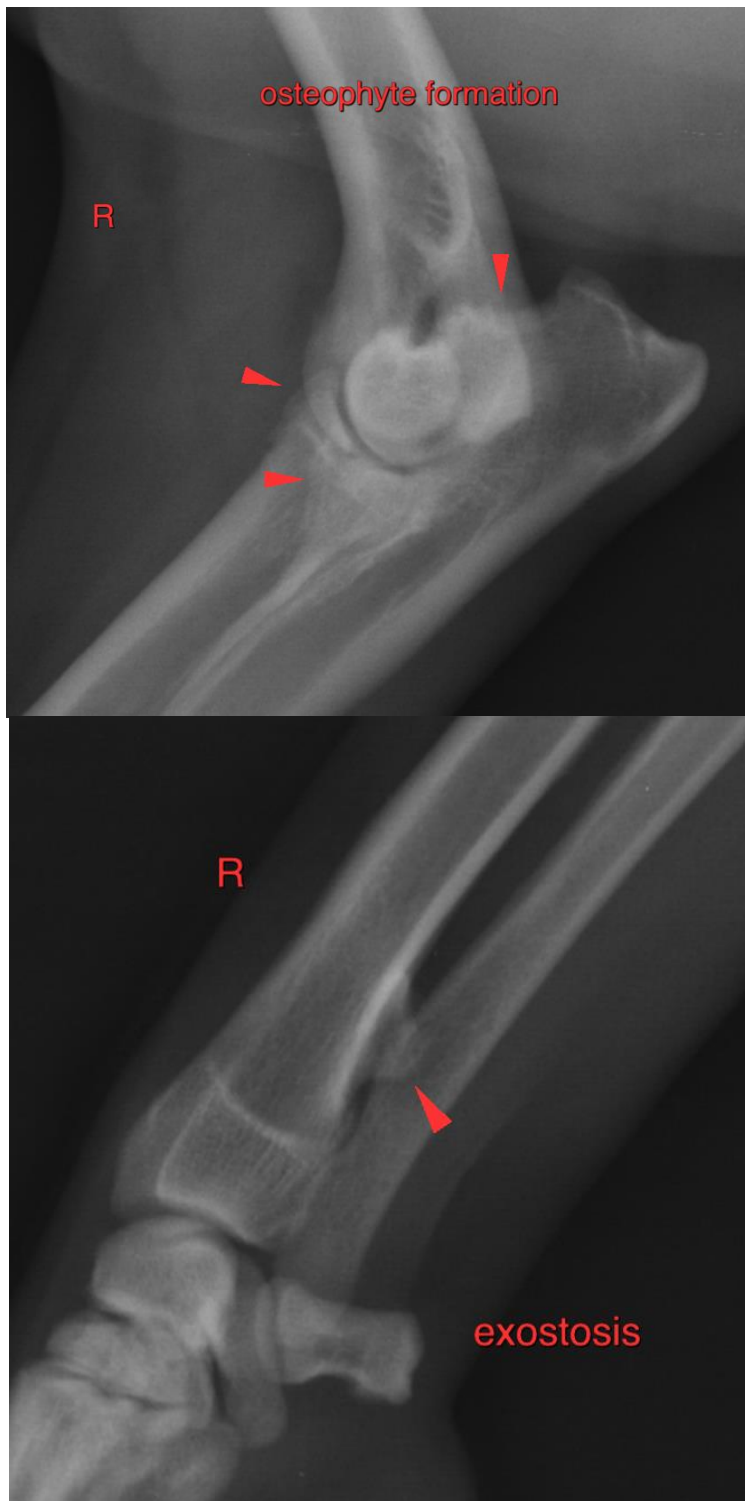Dr. Diane Heider

INVOICE

53134

DATE

7-27-22





PATIENT

Tess Shumaker

SPECIES

Canine

BREED

Lab Mix

SEX

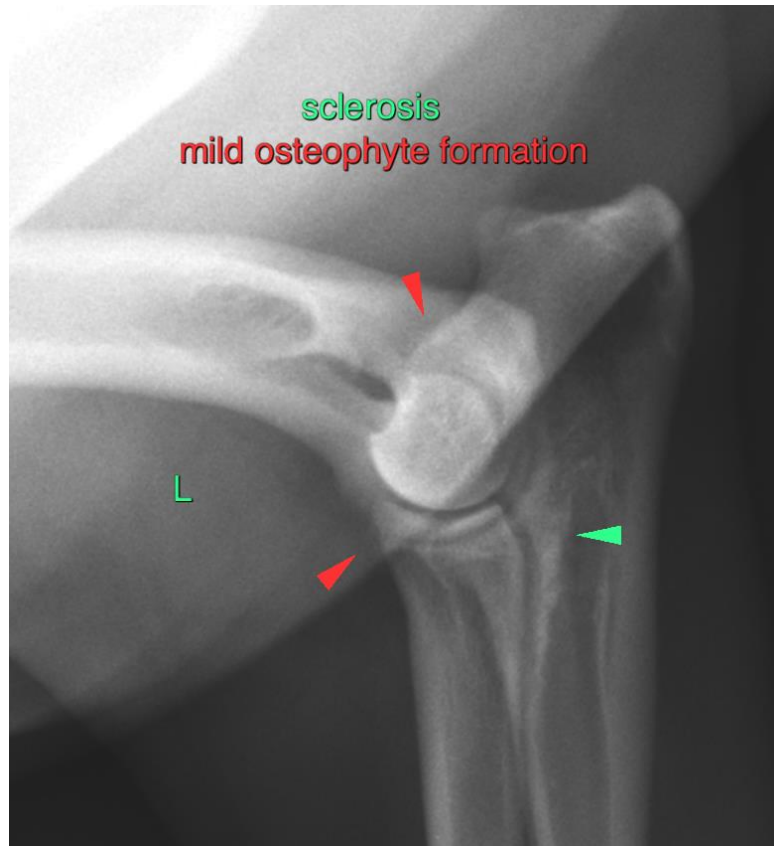
FS

AGE

6 Years, 3 Months

INTERPRETED BY

Sebastian Schaub, DVM
Dr. med. vet. DipECVDI



HOSPITAL NAME

Reid Veterinary
Hospital

REFERRING VET

Dr. Diane Heider

INVOICE

53134

DATE

7-27-22

The information and recommendations provided are based on the images presented by the referring veterinarian/sonographer. No evaluation can be communicated regarding pathology that was not visible in the image/video clips provided.

Thank you for this referral. If the clinical or image interpretation does not parallel your findings or if I can be of any further assistance please contact me.

Sebastian Schaub, Sebastian Schaub, DVM, Dr. med. vet. DipECVDI
sebast.schaub@gmail.com