

PATIENT

Brody Hanna-Albanese

PRESENTING CLINICAL SIGNS

Presented for annual exam and labs last week- pet had lost weight with little to no change in routine. O wanted to be proactive in case there was something going on. History of Sz controlled on phenobarbital with no Sz in past 4-5 years. Also hypothyroid. Pet had AUS today as well.

SPECIES

Canine

RADIOGRAPHIC STUDY OF THE THORAX & ABDOMEN

A complete set of radiographs of the thorax and abdomen is provided for review.

BREED

Golden Doodle

RADIOGRAPHIC FINDINGS

Thorax

The surrounding bony structures are within normal limits.

The extrathoracic soft tissues present homogeneous without abnormalities.

The heart is of normal size and shape, there is no evidence of cardiac chamber or vascular enlargement. The pulmonary vasculature is within normal limits.

SEX

Neutered Male

The cranial mediastinum presents the expected soft tissue opacity. The mediastinal width is less than twice the width of the vertebral column at the same level.

AGE

9 Years

The trachea is normal in diameter and presents the anticipated course. The luminal outline of the trachea is smooth.

The bronchial tree presents with thin walls and tapers uniformly towards the periphery as expected.

INTERPRETED BY

Sebastian Schaub, DVM
Dr. med. vet. DipECVDI

The lung parenchyma presents the expected architecture and opacity; the intrapulmonary vascular branching is seen up to the third order lung vessels.

The diaphragm is well delineated with even surface and the expected mild cranial bulging of the diaphragmatic cupola.

HOSPITAL NAME

Animal Hospital of Roxbury

Abdomen

Multifocal moderate spondylosis formation is seen along the lumbar spine. The periarticular bones of both coxofemoral joints present mild osteophyte new bone formation.

REFERRING VET

Dr. Jaime Elia

Two fat opaque swelling are seen along the subcutaneous tissue of the left abdominal wall.

The serosal detail is maintained throughout the peritoneal and retroperitoneal space.

The liver is appropriate in position, size and presents uniform opacity.

INVOICE

53130

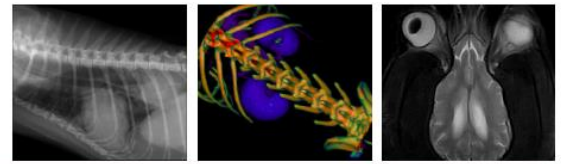
The splenic head is in the anticipated position and within normal limits for size and opacity. The splenic body and tail are considered normal for position, size, shape and opacity.

Both kidneys are seen and present with normal size, shape, delineation and opacity. The urinary bladder is in its anticipated position. No radiopaque calculi are noted throughout the upper and lower urinary tract.

DATE

7-27-22

The stomach is in its anticipated position and in the VD projection three soft tissue opaque roundish structures are appreciated in the lumen of the fundus.



PATIENT

Brody Hanna-Albanese

The small intestinal loops are of even diameter and non-dilated, a small amount of gas is seen within the small intestinal loops and considered within normal limits.

The colon is seen in the expected position and presents with appropriate content.

RADIOGRAPHIC DIAGNOSIS

SPECIES

Canine

- Soft tissue structures in the gastric lumen
- Degenerative osteoarthritis coxofemoral joints bilaterally, L>R
- Spondylosis deformans
- Normal lung

BREED

Golden Doodle

INTERPRETATION OF THE FINDINGS & FURTHER RECOMMENDATIONS

The soft tissue opacities in the gastric lumen are most consistent with dog treats, also the odds are low an intraluminal mural lesion bulging into the gastric lumen cannot be ruled out entirely. In case of doubt, gastroscopy could be used as advanced diagnostic tool.

SEX

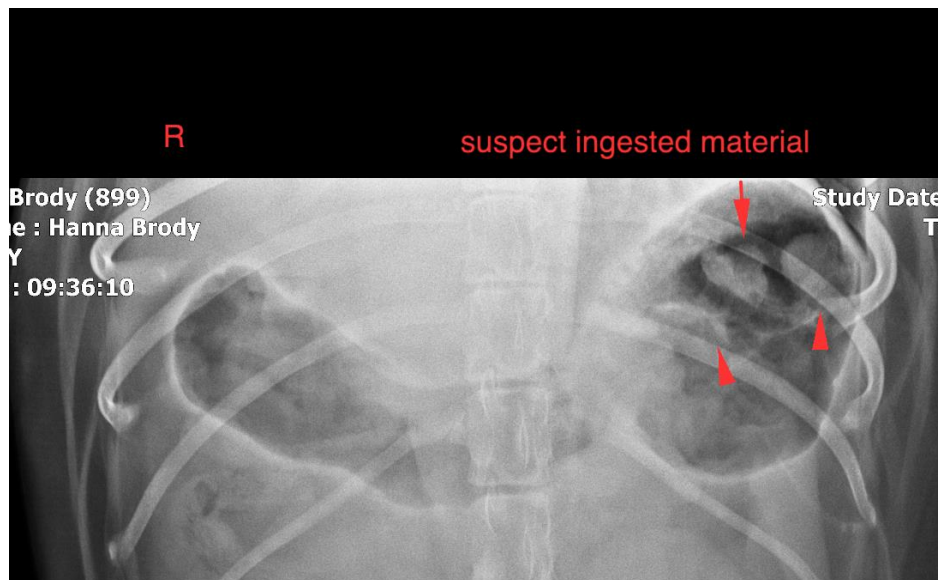
Neutered Male

AGE

9 Years

INTERPRETED BY

Sebastian Schaub, DVM
Dr. med. vet. DipECVDI



HOSPITAL NAME

Animal Hospital of Roxbury

REFERRING VET

Dr. Jaime Elia

The information and recommendations provided are based on the images presented by the referring veterinarian/sonographer. No evaluation can be communicated regarding pathology that was not visible in the image/video clips provided.

INVOICE

53130

Thank you for this referral. If the clinical or image interpretation does not parallel your findings or if I can be of any further assistance please contact me.

Sebastian Schaub, Sebastian Schaub, DVM, Dr. med. vet. DipECVDI
sebast.schaub@gmail.com

DATE

7-27-22