



PATIENT

Loki Butler

PRESENTING CLINICAL SIGNS

Limping on and off on right hind leg since May, not getting worse but not getting any better. Twisted it at the park on Friday, acute lameness since then on right hind leg. Touch touching only. On PE - painful on palpation of right stifle, swollen, drawer sign and clicking.

SPECIES

Canine

RADIOGRAPHIC STUDY OF THE LUMBAR SPINE AND STIFLE JOINTS

Radiographs of the lumbar spine in a lateral view are provided for review.

BREED

Shepard X

RADIOGRAPHIC FINDINGS

The vertebral endplates L1/L2 and L2/L3 present mild ventral spondylosis formation. The remainder of the osseous and surrounding soft tissue structures of the lumbar spine are within normal limits.

SEX

MN

The volume of the right thigh musculature is significantly decreased.

The periarticular bones of the right stifle joint present moderate osteophyte new bone formation and a mild to moderate intracapsular soft tissue swelling.

AGE

8.9 Years

The left stifle joint presents smooth margins of the periarticular bones and without evidence of intracapsular swelling.

INTERPRETED BY

Sebastian Schaub, DVM
Dr. med. vet. DipECVDI

RADIOGRAPHIC DIAGNOSIS

- Moderate degenerative osteoarthritis right stifle joint
- Mild articular swelling right stifle joint
- Disuse atrophy right thigh musculature
- Spondylosis deformans

HOSPITAL NAME

Sunridge Veterinary
Clinic

INTERPRETATION OF THE FINDINGS & FURTHER RECOMMENDATIONS

The radiographic study is consistent with right sided chronic degenerative osteoarthritis with concomitant joint effusion of the stifle joint. In combination with the clinical findings, underlying pathology of the cranial cruciate ligament + meniscal disease is likely.

Secondary disuse atrophy right thigh musculature.

REFERRING VET

Dr. Magill

INVOICE

53088

DATE

7-26-22



PATIENT

Loki Butler

SPECIES

Canine

BREED

Shepard X

SEX

MN

AGE

8.9 Years

INTERPRETED BY

Sebastian Schaub, DVM
Dr. med. vet. DipECVDI

HOSPITAL NAME

Sunridge Veterinary
Clinic

REFERRING VET

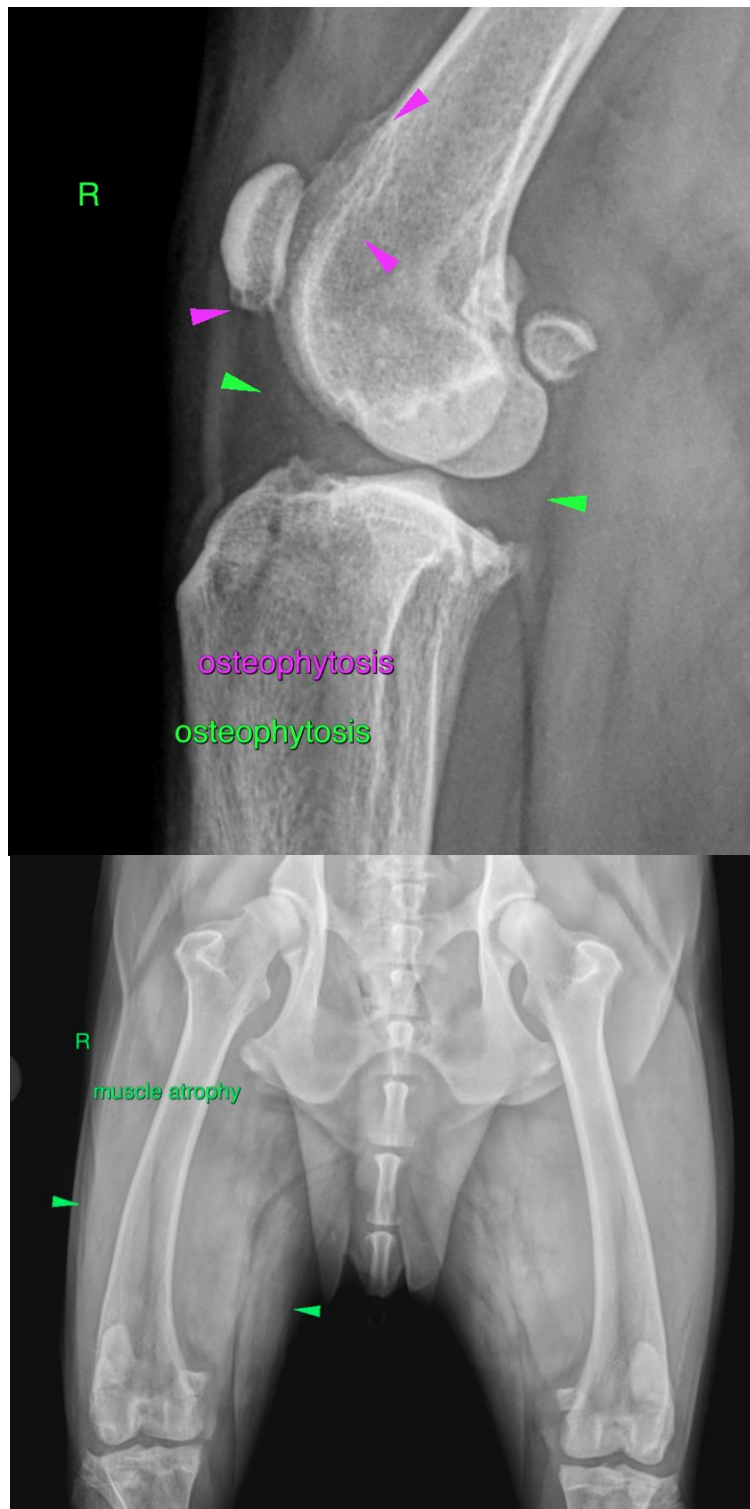
Dr. Magill

INVOICE

53088

DATE

7-26-22





PATIENT

Loki Butler

SPECIES

Canine

The information and recommendations provided are based on the images presented by the referring veterinarian/sonographer. No evaluation can be communicated regarding pathology that was not visible in the image/video clips provided.

BREED

Shepard X

Thank you for this referral. If the clinical or image interpretation does not parallel your findings or if I can be of any further assistance please contact me.

Sebastian Schaub, Sebastian Schaub, DVM, Dr. med. vet. DipECVDI
sebast.schaub@gmail.com

SEX

MN

AGE

8.9 Years

INTERPRETED BY

Sebastian Schaub, DVM
Dr. med. vet. DipECVDI

HOSPITAL NAME

Sunridge Veterinary
Clinic

REFERRING VET

Dr. Magill

INVOICE

53088

DATE

7-26-22