



PATIENT

Banjo Hollyer

PRESENTING CLINICAL SIGNS

HBC yesterday, broken left pelvis
Abnormal PE/Chem/CBC/UA Results: mild anemia

SPECIES

Feline

RADIOGRAPHIC STUDY OF THE PELVIS

Radiographs of the pelvis in two imaging planes are provided for review.

BREED

Siamese

RADIOGRAPHIC FINDINGS

In the subcutaneous tissue dorsal to L5, small gas inclusions is visible.

The left iliac wing & entire left hemipelvis are deviated cranially and the joint space of the left sacroiliac joint is widened. A small isolated osseous lamella is seen at the medial aspect of the left iliac wing, level with the articular surface.

SEX

MN

The cranial ramus of pubic bone bilaterally presents with a short oblique fracture and a sagittal fracture of the left ischial bone level with the symphysis is present.

A diffuse soft tissue swelling is seen ventral to L7 and S1.

AGE

1 Year

RADIOGRAPHIC DIAGNOSIS

- Traumatic left sided cranial luxation of the sacroiliac joint with small avulsion fragment of the left ala of the sacrum
- Acute traumatic multiple fractures of the pelvic floor
- Small gas inclusions subcutaneous tissue dorsal to L5
- Suspect hematoma formation ventral to L7/S1

INTERPRETED BY

Sebastian Schaub, DVM
Dr. med. vet. DipECVDI

INTERPRETATION OF THE FINDINGS & FURTHER RECOMMENDATIONS

The radiographic study is fitting the history of blunt pelvic trauma with left sided luxation of the sacroiliac joint and multiple fractures of the pelvic floor. Surgical management of the luxation of the left sacroiliac joint is considered beneficial.

The small gas inclusion dorsal to L5 can be a sequela to subcutaneous injection or wound.

HOSPITAL NAME

Balmy Beach Pet
Hospital

REFERRING VET

Dr. Singh

INVOICE

53076

DATE

7-25-22



PATIENT

Banjo Hollyer

SPECIES

Feline

BREED

Siamese

SEX

MN

AGE

1 Year

INTERPRETED BY

Sebastian Schaub, DVM
Dr. med. vet. DipECVDI

HOSPITAL NAME

Balmy Beach Pet
Hospital

REFERRING VET

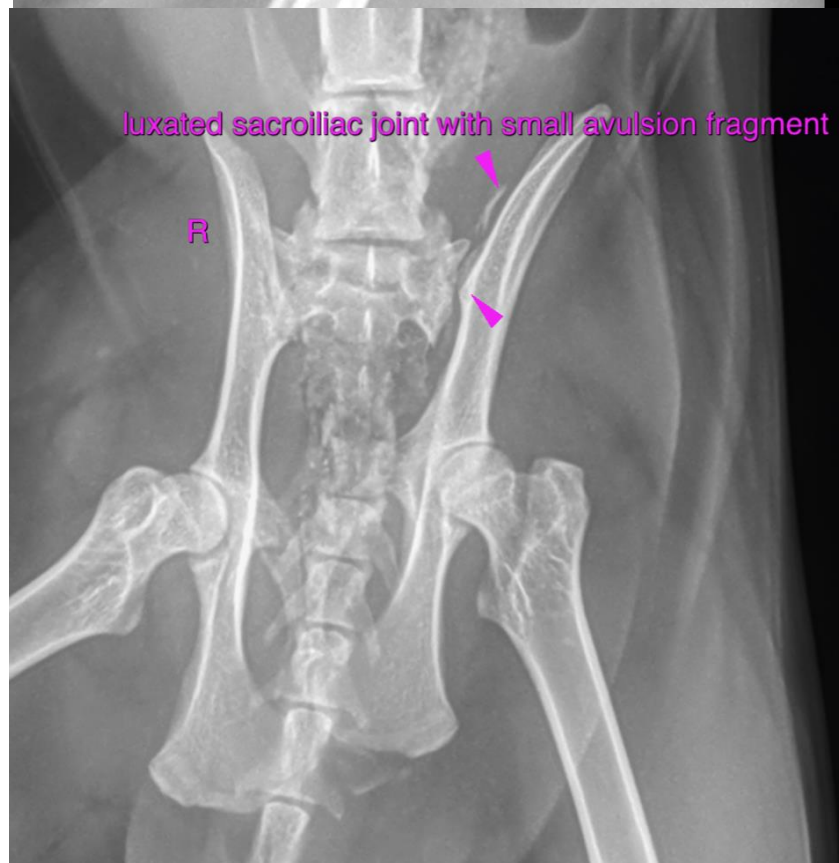
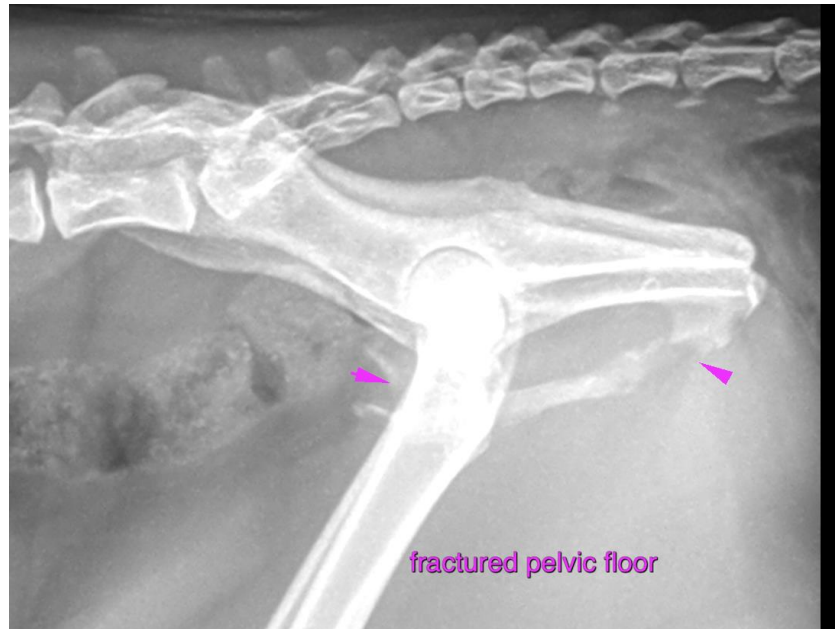
Dr. Singh

INVOICE

53076

DATE

7-25-22





PATIENT

Banjo Hollyer

SPECIES

Feline

BREED

Siamese

SEX

MN

AGE

1 Year

INTERPRETED BY

Sebastian Schaub, DVM
Dr. med. vet. DipECVDI

HOSPITAL NAME

Balmy Beach Pet
Hospital

REFERRING VET

Dr. Singh

INVOICE

53076

DATE

7-25-22

The information and recommendations provided are based on the images presented by the referring veterinarian/sonographer. No evaluation can be communicated regarding pathology that was not visible in the image/video clips provided.

Thank you for this referral. If the clinical or image interpretation does not parallel your findings or if I can be of any further assistance please contact me.

Sebastian Schaub, Sebastian Schaub, DVM, Dr. med. vet. DipECVDI
sebast.schaub@gmail.com