



PATIENT

Porsche Romain

PRESENTING CLINICAL SIGNS

Patient with honking cough , has been on and off , has been treated for kennel cough , had a rough night the day before the visit , on PE showed abdominal breathing , discomfort on palpation and eye cataract .

SPECIES

Canine

RADIOGRAPHIC STUDY OF THE THORAX

Radiographs of the thorax in three imaging planes are provided for review. Radiographs are provided in JPEG file format.

BREED

Pug

RADIOGRAPHIC FINDINGS

The body condition score is 7/9.

SEX

Female Spayed

Multifocal mild spondylosis formation is seen along the thoracic spine. The periarticular bones of the left shoulder joint present moderate osteophyte new bone formation.

The extrathoracic soft tissues present homogeneous without abnormalities.

The heart is of normal size and shape, there is no evidence of cardiac chamber or vascular enlargement. The pulmonary vasculature is within normal limits.

AGE

12 Years

The mediastinum is moderately widened by fat.

Significant dorsoventral flattening of the caudal cervical and intrathoracic segment of the trachea is appreciated.

INTERPRETED BY

Sebastian Schaub, DVM
Dr. med. vet. DipECVDI

In the right lateral view, the principal bronchi cannot be clearly appreciated.

The lung parenchyma presents a generalized mild to moderate ground glass opacity.

The diaphragm is well delineated with even surface and the expected mild cranial bulging of the diaphragmatic cupola.

HOSPITAL NAME

Wilson Road Vet
Clinic

RADIOGRAPHIC DIAGNOSIS

- Obesity
- Significant tracheal collapse
- Suspect bronchial collapse
- Generalized unstructured interstitial lung pattern – considered as sequela to nutritional status and hypoinflation of the lung parenchyma
- Degenerative osteoarthritis left shoulder joint
- Spondylosis deformans

REFERRING VET

Dr, Nancy Abdelmalak

INVOICE

53043

INTERPRETATION OF THE FINDINGS & FURTHER RECOMMENDATIONS

The tracheal collapse is a plausible cause for the history of cough and might be accompanied by bronchial collapse. Tracheoscopy can be used for grading of the tracheal collapse and rule in/out accompanying bronchial collapse – tracheoscopy/bronchoscopy can also be complementing by BAL to screen for secondary inflammatory lower airway disease, potentially deteriorating clinical signs.

DATE

7-23-22



PATIENT

Porsche Romain

SPECIES

Canine

BREED

Pug

SEX

Female Spayed

AGE

12 Years

INTERPRETED BY

Sebastian Schaub, DVM
Dr. med. vet. DipECVDI

HOSPITAL NAME

Wilson Road Vet
Clinic

REFERRING VET

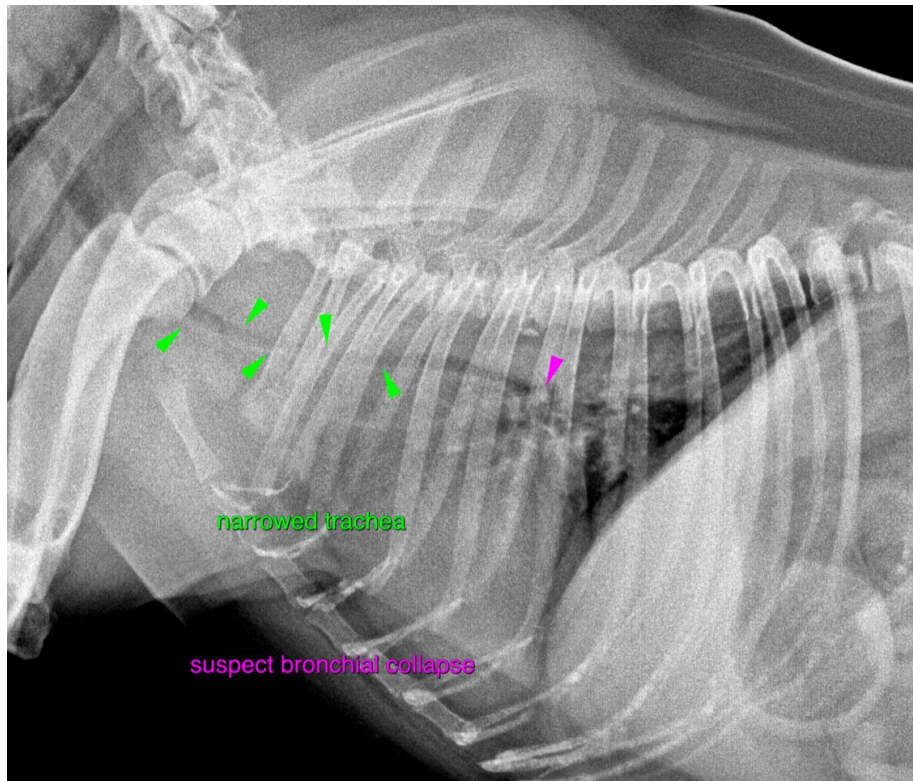
Dr, Nancy Abdelmalak

INVOICE

53043

DATE

7-23-22



The information and recommendations provided are based on the images presented by the referring veterinarian/sonographer. No evaluation can be communicated regarding pathology that was not visible in the image/video clips provided.

Thank you for this referral. If the clinical or image interpretation does not parallel your findings or if I can be of any further assistance please contact me.

Sebastian Schaub, Sebastian Schaub, DVM, Dr. med. vet. DipECVDI
sebast.schaub@gmail.com