



PATIENT PRESENTING CLINICAL SIGNS

PATIENT Roxy Walton History: noticed swelling on Monday, gave antihistamine injection did not help. Visited another vet who thought it might be cancer pulled fluid for cytology/culture, did dental rads, and suggested CT. Abnormal PE/Chem/CBC/UA Results: Culture/cytology has been submitted - results not back yet.

SPECIES On Cyclosporine for perineal fistulas. Visited another vet who thought it might be cancer pulled fluid for cytology/culture, did dental rads, and suggested CT.

Canine

COMPUTED TOMOGRAPHIC STUDY OF THE SKULL

BREED A high resolution pre- and post-contrast CT study of the skull is provided for review.

German Shepherd COMPUTED TOMOGRAPHIC FINDINGS

Parts of the crown of triadan 301 & 401 are absent.

SEX

SEX Spayed Female In the rostroventral aspect of the left nasal cavity, a small amount of fluid attenuating material is appreciated. The nasal cavity presents the expected aerated spaces between thin & even conchae and turbinates with smooth mucosal lining. The soft tissues surrounding the nose are partially overexposed and burned out.

AGE

AGE 10 Years Both temporomandibular joints present congruent joint spaces with even subchondral bone surfaces and are considered within normal limits.

INTERPRETED BY

Both tympanic bullae are aerated, the mucosal lining is not seen, the bony wall is smooth and thin. Incidental tympanic osseous spicules are seen within the tympanic bulla bilaterally. The external ear canals are within normal limits.

Sebastian Schaub,
DVM Dr. med. vet.
DipECVDI

The brain presents no deviation from normal anatomy and symmetry. The brain parenchyma is homogeneous and within normal limits for attenuation and distribution of contrast enhancement.

HOSPITAL NAME

The ventricular system is non-dilated and symmetric. The left mandibular lymph nodes are prominent.

Mountain West VH

COMPUTED TOMOGRAPHIC DIAGNOSIS

REFERRING VET

Dr. Simmons

- Lymphadenopathy left mandibular lymph nodes
- Complicated dental fracture 301&401
- Left sided mild rhinitis

INTERPRETATION OF THE FINDINGS & FURTHER RECOMMENDATIONS

INVOICE

16726

Unfortunately, the superficial soft tissue structures of the skull are overexposed and burned out, no soft tissue swelling is appreciated. Repeating the CT scan with different machine settings and lower dosage values can be considered to visualize the superficial soft tissues of the skull.

DATE

7/22/22



PATIENT

The lymphadenopathy of the left mandibular lymph nodes is suggestive for reactive hyperplasia, possibly due to inflammatory process in the tributary region.

Roxy Walton

SPECIES

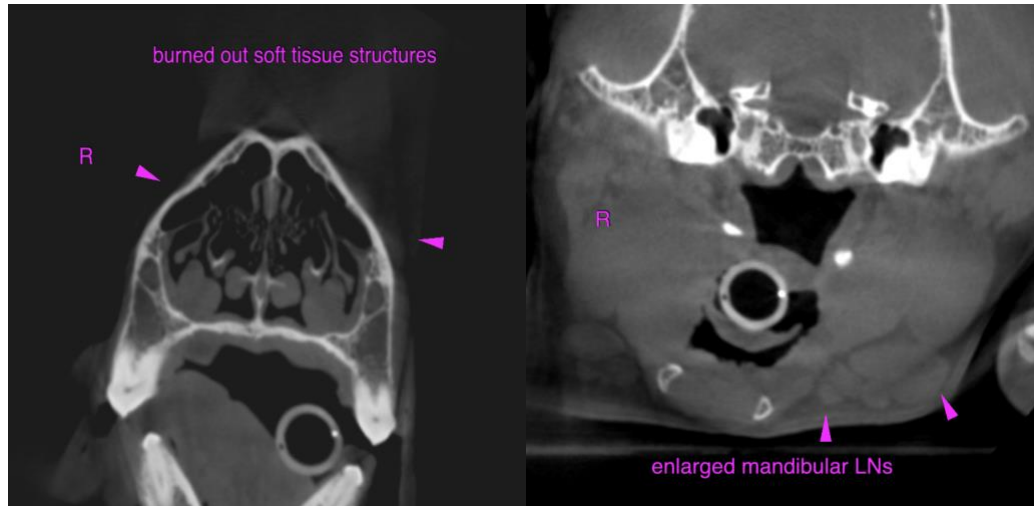
Canine

BREED

German Shepherd

SEX

Spayed Female



AGE

10 Years

The information and recommendations provided are based on the images presented by the referring veterinarian/sonographer. No evaluation can be communicated regarding pathology that was not visible in the image/video clips provided.

Thank you for this referral. If the clinical or image interpretation does not parallel your findings or if I can be of any further assistance please contact me.

INTERPRETED BY

Sebastian Schaub,
DVM Dr. med. vet.
DipECVDI

Sebastian Schaub, Sebastian Schaub, DVM, Dr. med. vet. DipECVDI
sebast.schaub@gmail.com

HOSPITAL NAME

Mountain West VH

REFERRING VET

Dr. Simmons

INVOICE

16726

DATE

7/22/22