



PATIENT

Murphy Smelser

PRESENTING CLINICAL SIGNS

Intermittent bouts of severe neck pain. Resolves with medical management. Otherwise healthy
Abnormal PE/Chem/CBC/UA Results: WNL

SPECIES

Canine

COMPUTED TOMOGRAPHY OF THE CERIVCAL & THORACIC SPINE

A high resolution pre- and post-contrast CT study of the cervical and thoracic spine is provided for review.

BREED

Corgi

COMPUTED TOMOGRAPHIC FINDINGS

C3 - C5 are fused and present misshapen transverse processes bilaterally; the respective neuroforamina are misshapen and the left neuroforamen of the spinal nerve C5 is moderately narrowed.

SEX

MN

The remainder of the cervical spine and the thoracic spine present without abnormalities.

COMPUTED TOMOGRAPHIC DIAGNOSIS

- Block vertebra C3-C5 with potential neuroforaminal stenosis right spinal nerve C5

AGE

1

INTERPRETATION OF THE FINDINGS & FURTHER RECOMMENDATIONS

The findings are consistent with segmentation disorder of the cervical spine with C3 to C5 being fused to one vertebra with malformed transverse processes and neuroforamina bilaterally. The altered biomechanics and malformed neuroforamina are a predisposing factor for pain – there is an increased risk for discopathy of the C2/C3 and C5/C6, at this point no evidence of compressive myelopathy. Management is limited to palliative options.

INTERPRETED BY

Sebastian Schaub, DVM
Dr. med. vet. DipECVDI

HOSPITAL NAME

Wilvet Salem

REFERRING VET

Dr. Emi Menzen

INVOICE

53040

DATE

7-22-22



PATIENT

Murphy Smelser

SPECIES

Canine

BREED

Corgi

SEX

MN

AGE

1

INTERPRETED BY

Sebastian Schaub, DVM
Dr. med. vet. DipECVDI

HOSPITAL NAME

Wilvet Salem

REFERRING VET

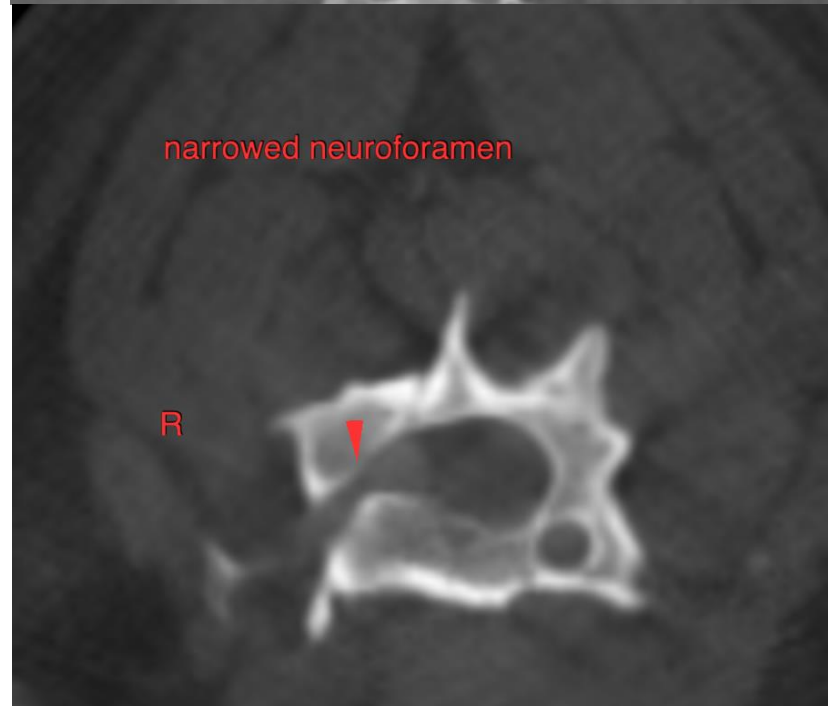
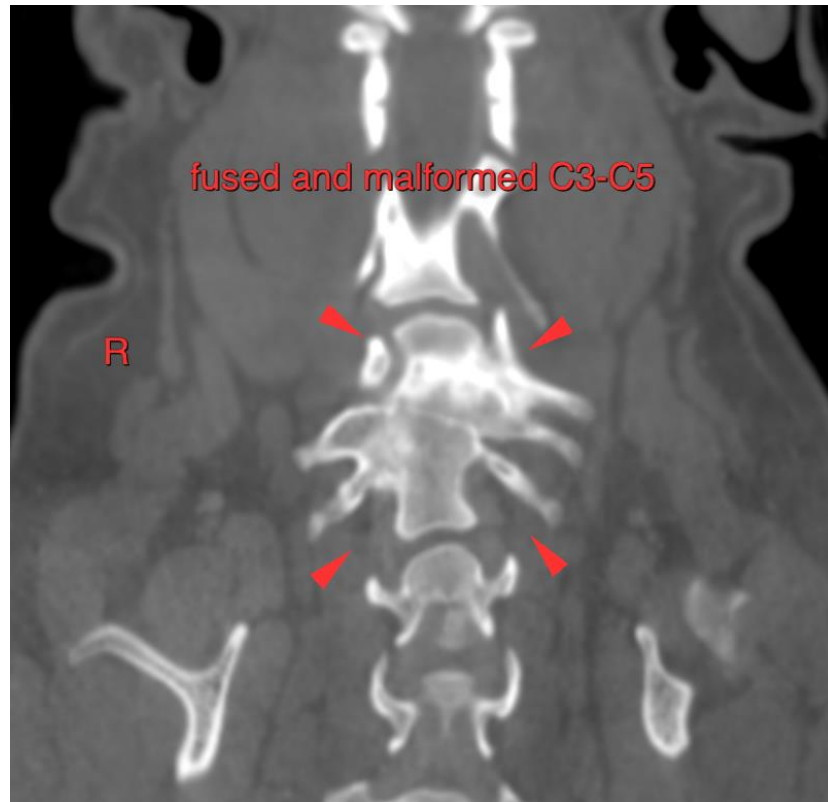
Dr. Emi Menzen

INVOICE

53040

DATE

7-22-22





PATIENT

Murphy Smelser

The information and recommendations provided are based on the images presented by the referring veterinarian/sonographer. No evaluation can be communicated regarding pathology that was not visible in the image/video clips provided.

SPECIES

Canine

Thank you for this referral. If the clinical or image interpretation does not parallel your findings or if I can be of any further assistance please contact me.

Sebastian Schaub, Sebastian Schaub, DVM, Dr. med. vet. DipECVDI
sebast.schaub@gmail.com

BREED

Corgi

SEX

MN

AGE

1

INTERPRETED BY

Sebastian Schaub, DVM
Dr. med. vet. DipECVDI

HOSPITAL NAME

Wilvet Salem

REFERRING VET

Dr. Emi Menzen

INVOICE

53040

DATE

7-22-22