



**PATIENT PRESENTING CLINICAL SIGNS**

Bailey Masters History: Swelling of face, painful opening jaw, can't retropulse eye  
Abnormal PE/Chem/CBC/UA Results: ALP 545, CPK 386, rest wnl

**SPECIES COMPUTED TOMOGRAPHIC STUDY OF THE SKULL**

Canine A high resolution pre- and post-contrast CT study of the skull is provided for review.

**COMPUTED TOMOGRAPHIC FINDINGS**

**BREED**

Border Collie Mix

The pictured parts of the dentition are complete and unremarkable in all jaw quadrants.

The nasal cavity presents the expected aerated spaces between thin & even conchae and turbinates with smooth mucosal lining.

**SEX**

Spayed Female

In the caudal aspect of the right orbit, a uniform soft tissue attenuating and heterogeneous contrast enhancing mass is seen, measuring 5.4 x 3.0 x 4.7 cm in size. The mass is occupying the entire caudal aspect of the right orbit and the right ocular bulb is deviated dorsally and rostrally. In the caudal aspect the right retrobulbar mass is extending along the laterodorsal aspect of the calvarium up to the level of the right parietal bone – the associated osseous structures (including the medial wall of the left orbit up to the parietal bone) present permeative osteolytic lesions and immature periosteal new bone formation. The right retrobulbar mass is protruding into the right frontal sinus and bulging into the cranial fossa, depressing the right parietal lobe of the brain.

**AGE**

12 Years 8 Months

**INTERPRETED BY**

Sebastian Schaub,  
DVM Dr. med. vet.  
DipECVDI

In the subcutaneous tissue rostral to the right pinna, a multilobulated, well-defined mineralizing body is seen.

Both temporomandibular joints present congruent joint spaces with even subchondral bone surfaces and are considered within normal limits.

**HOSPITAL NAME**

Blairstown AH

Both tympanic bullae are aerated, the mucosal lining is not seen, the bony wall is smooth and thin. The external ear canals are within normal limits.

**REFERRING VET**

Dr. Summers

The submandibular and medial retropharyngeal lymph nodes are small and elongated with a normal short-to-long-axis-ratio is < 0.5, the attenuation and contrast enhancement pattern is uniform.

**COMPUTED TOMOGRAPHIC DIAGNOSIS**

**INVOICE**

16483

- Biologically aggressive right sided retrobulbar soft tissue neoplasia with polyostotic aggressive osteolytic lesions of the associated osseous structures and perforation of the cranial fossa
- Secondary right sided exophthalmos
- Suspect subcutaneous dystrophic mineralization rostral to the right pinna

**INTERPRETATION OF THE FINDINGS & FURTHER RECOMMENDATIONS**

**DATE**

7/22/22



**PATIENT**

Bailey Masters

The CT study is consistent with a right sided primary retrobulbar soft tissue neoplasia, perforating the cranial fossa and right frontal sinus. Differentials include melanoma, fibrosarcoma, osteosarcoma, hemangiosarcoma, adenocarcinoma, other. FNA sampling of the retrobulbar mass can be considered as advanced diagnostic tool. The chances of radiation therapy might be discussed with oncologist, based on the results of the advanced diagnostic tests. The long term prognosis is considered very guarded.

**SPECIES**

Canine

Consider full tumor staging.

**BREED**

Border Collie Mix

**SEX**

Spayed Female

**AGE**

12 Years 8 Months

**INTERPRETED BY**

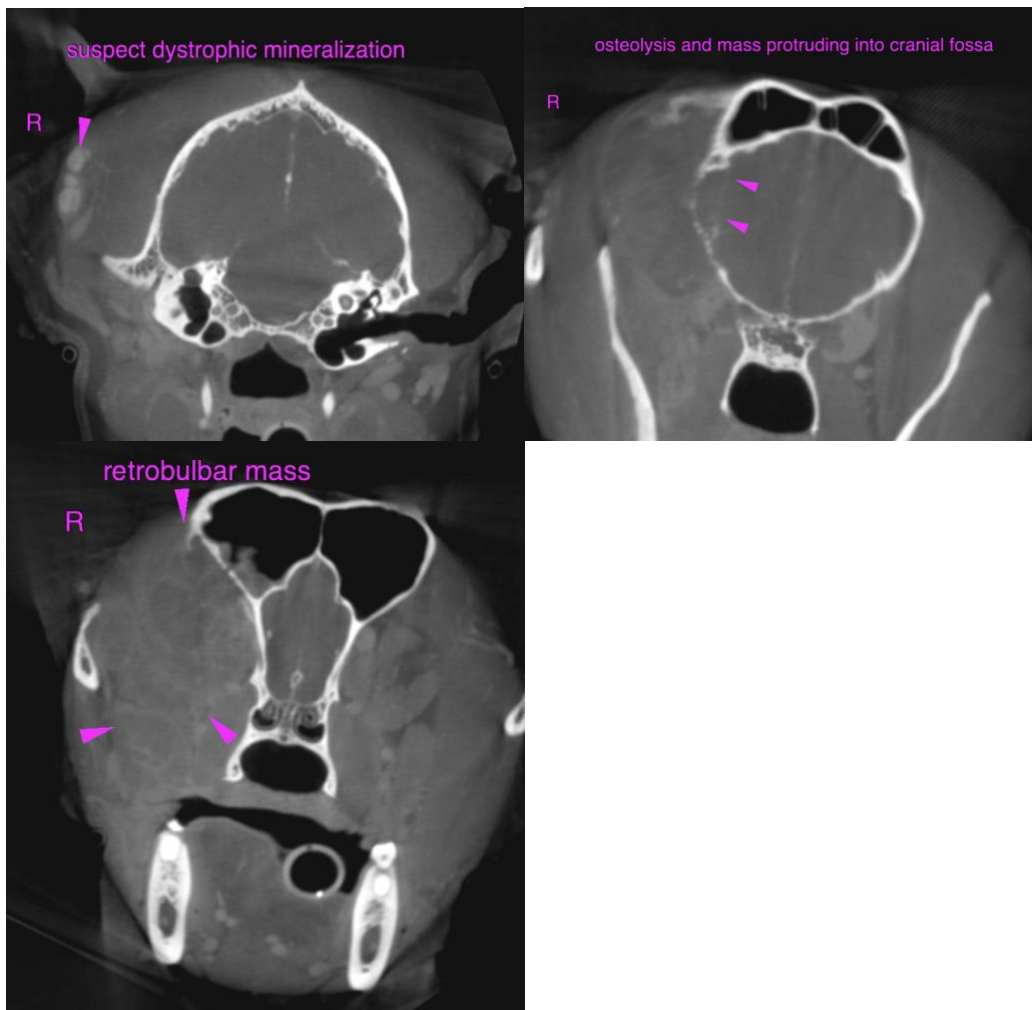
Sebastian Schaub,  
DVM Dr. med. vet.  
DipECVDI

**HOSPITAL NAME**

Blairstown AH

**REFERRING VET**

Dr. Summers



**INVOICE**

16483

The information and recommendations provided are based on the images presented by the referring veterinarian/sonographer. No evaluation can be communicated regarding pathology that was not visible in the image/video clips provided.

**DATE**

7/22/22

Thank you for this referral. If the clinical or image interpretation does not parallel your findings or if I can be of any further assistance please contact me.



**PATIENT**

Bailey Masters

**Sebastian Schaub**, Sebastian Schaub, DVM, Dr. med. vet. DipECVDI  
sebast.schaub@gmail.com

**SPECIES**

Canine

**BREED**

Border Collie Mix

**SEX**

Spayed Female

**AGE**

12 Years 8 Months

**INTERPRETED BY**

Sebastian Schaub,  
DVM Dr. med. vet.  
DipECVDI

**HOSPITAL NAME**

Blairstown AH

**REFERRING VET**

Dr. Summers

**INVOICE**

16483

**DATE**

7/22/22