



PATIENT PRESENTING CLINICAL SIGNS

PATIENT Lucy Nucci
SPECIES Canine
BREED Beagle

History: Lucy_has been sick for about a month. around July 4th she was vomiting and having diarrhea - went to regular vet got a Cerenia injection and sent home with Tylosin, side effects stopped right away. Was off the Tylosin for a day and started vomiting again. last dose of Tylosin was Saturday, vomited on Sunday. started shaking on Saturday. took her back to the regular vet and they said there was low WBC and a slight abnormalities and bacteria in her stool sample. constantly shaking unless she lays down. seems alert still. hasn't eaten since Tuesday night @7pm - tried feeding a lot of different foods and nothing interested her. was tested for Addison's disease and it was negative. CBC/Chem at rDVM was normal. Tilting her head to the right yesterday. lack of coordination and balance when shaking. Sent to Bridgwater Vet for CT. Prednisone 5mg around 11am July 19 (hasn't been helping). Had Methocarbamol July 19. DDX - toxicity, Wobbler's, cerebellar disease, brain lesion. viral infection

COMPUTED TOMOGRAPHIC STUDY OF THE SKULL AND ENTIRE SPINE

SEX

SEX Spayed Female
 A high resolution pre- and post-contrast CT study of the skull and abdomen and a post-contrast CT study of the thorax are provided for review.

AGE

AGE 3 Years 9 Months

COMPUTED TOMOGRAPHIC FINDINGS

Skull

The pictured parts of the dentition are complete and unremarkable in all jaw quadrants.

INTERPRETED BY

Sebastian Schaub,
 DVM Dr. med. vet.
 DipECVDI

The nasal cavity presents the expected aerated spaces between thin & even conchae and turbinates with smooth mucosal lining.

Both temporomandibular joints present congruent joint spaces with even subchondral bone surfaces and are considered within normal limits.

HOSPITAL NAME

Bridgwater VH & WC

Both tympanic bullae are aerated, the mucosal lining is not seen, the bony wall is smooth and thin. The external ear canals are within normal limits.

REFERRING VET

Dr. Dhaliwal

The brain presents no deviation from normal anatomy and symmetry. The brain parenchyma is homogeneous and within normal limits for attenuation and distribution of contrast enhancement. The lateral ventricles are asymmetric, R>L.

The submandibular and medial retropharyngeal lymph nodes are small and elongated with a normal short-to-long-axis-ratio is < 0.5, the attenuation and contrast enhancement pattern is uniform.

INVOICE

23602

Spine

Mild central mineralization of the intervertebral discs along the cervical spine.

DATE

7/21/23



PATIENT The osseous and soft tissue structures of the thoracic spine are within normal limits.

Lucy Nucci The lumbosacral intervertebral disc is bulging into the vertebral canal, occupying approximately 20% of the cross-sectional area of the vertebral canal at the same level.

SPECIES COMPUTED TOMOGRAPHIC DIAGNOSIS

- Mild intervertebral disc protrusion L7/S1 without compression of the caudal equina fibers
- Chondroid disc degeneration multifocal along the cervical spine
- Normal brain but incidental asymmetry of the lateral ventricles

BREED INTERPRETATION OF THE FINDINGS & FURTHER RECOMMENDATIONS

Beagle The CT study reveals no clinically relevant macromorphological abnormalities, explaining the neurological clinical signs. In case of strong clinical suspicion for intraparenchymal changes of the CNS, workup can be complemented by a MRI study.

SEX

Spayed Female

AGE

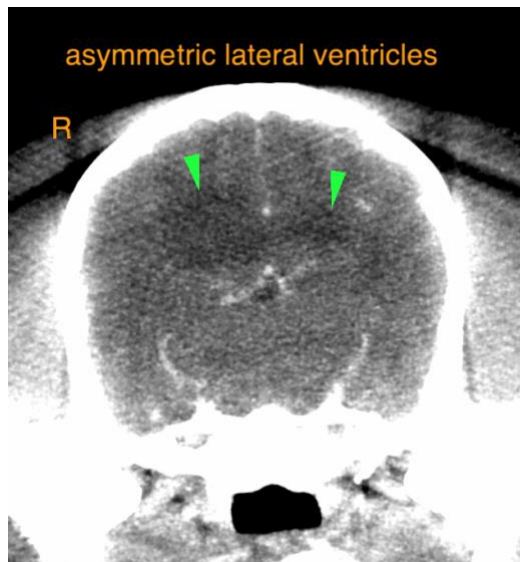
3 Years 9 Months

INTERPRETED BY

Sebastian Schaub,
DVM Dr. med. vet.
DipECVDI

HOSPITAL NAME

Bridwater VH & WC



The information and recommendations provided are based on the images presented by the referring veterinarian/sonographer. No evaluation can be communicated regarding pathology that was not visible in the image/video clips provided.

REFERRING VET

Dr. Dhaliwal Thank you for this referral. If the clinical or image interpretation does not parallel your findings or if I can be of any further assistance please contact me.

INVOICE

23602 Sebastian Schaub, Sebastian Schaub, DVM, Dr. med. vet. DipECVDI
info@sonopath.com

DATE

7/21/23



PATIENT

Lucy Nucci

SPECIES

Canine

BREED

Beagle

SEX

Spayed Female

AGE

3 Years 9 Months

INTERPRETED BY

Sebastian Schaub,
DVM Dr. med. vet.
DipECVDI

HOSPITAL NAME

Bridwater VH & WC

REFERRING VET

Dr. Dhaliwal

INVOICE

23602

DATE

7/21/23