



PATIENT PRESENTING CLINICAL SIGNS

Vera Saddler history of chronic sneezing with blood for past couple of years - on cortisone (prednisolone) for couple of years - today presented to us with swelling on face (L side) with a kind of 2mm cut/opening at the inner canthus of the upper L eyelid. In physical exam, lots of puss coming from this opening/cut - need to r/o any bone lysis or neoplasia or sinusitis

SPECIES

Feline

RADIOGRAPHIC STUDY OF THE SKULL

Radiographs of the skull in multiple imaging planes are provided for review.

BREED

DSH

RADIOGRAPHIC FINDINGS

A moderate homogeneous soft tissue swelling is appreciated at the medial aspect of the left ocular bulb. The left nasal cavity presents a generalized soft tissue opacification. The wall of the left frontal sinus presents moderate hyperostosis. The left alveolar process of the maxillary bone presents regions with moth eaten osteolysis.

SEX

Spayed Female

Multiple teeth are absent.

The tympanic bullae bilaterally are aerated and present a smooth osseous lining.

AGE

14 Years

The pharynx is aerated.

RADIOGRAPHIC DIAGNOSIS

INTERPRETED BY

Sebastian Schaub, DVM
Dr. med. vet. DipECVDI

- History of soft tissue swelling medial aspect left eye
- Left sided nasal soft tissue opacification
- Suspect osteolytic lesions left maxillary bone
- Hyperostosis left frontal sinus – sequela to rhinitis/sinusitis
- Multiple absent teeth

HOSPITAL NAME

Truscott Animal Hospital

INTERPRETATION OF THE FINDINGS & FURTHER RECOMMENDATIONS

The findings are concerning for biologically aggressive disease originating from the left nasal cavity – and primary nasal neoplasia is considered likely. As the osteolytic lesions appear to be centered on triadan 208, dental abscess is a potential, but appears less likely. Rhinoscopy including biopsy would be ideal for further workup. A CT study of the skull will also allow better evaluation of the osseous structures and extend of the potential nasal mass.

REFERRING VET

Dr. Medhat Meawad

INVOICE

53028

DATE

7-21-22



PATIENT

Vera Saddler

SPECIES

Feline

BREED

DSH

SEX

Spayed Female

AGE

14 Years

INTERPRETED BY

Sebastian Schaub, DVM
Dr. med. vet. DipECVDI

HOSPITAL NAME

Truscott Animal
Hospital

REFERRING VET

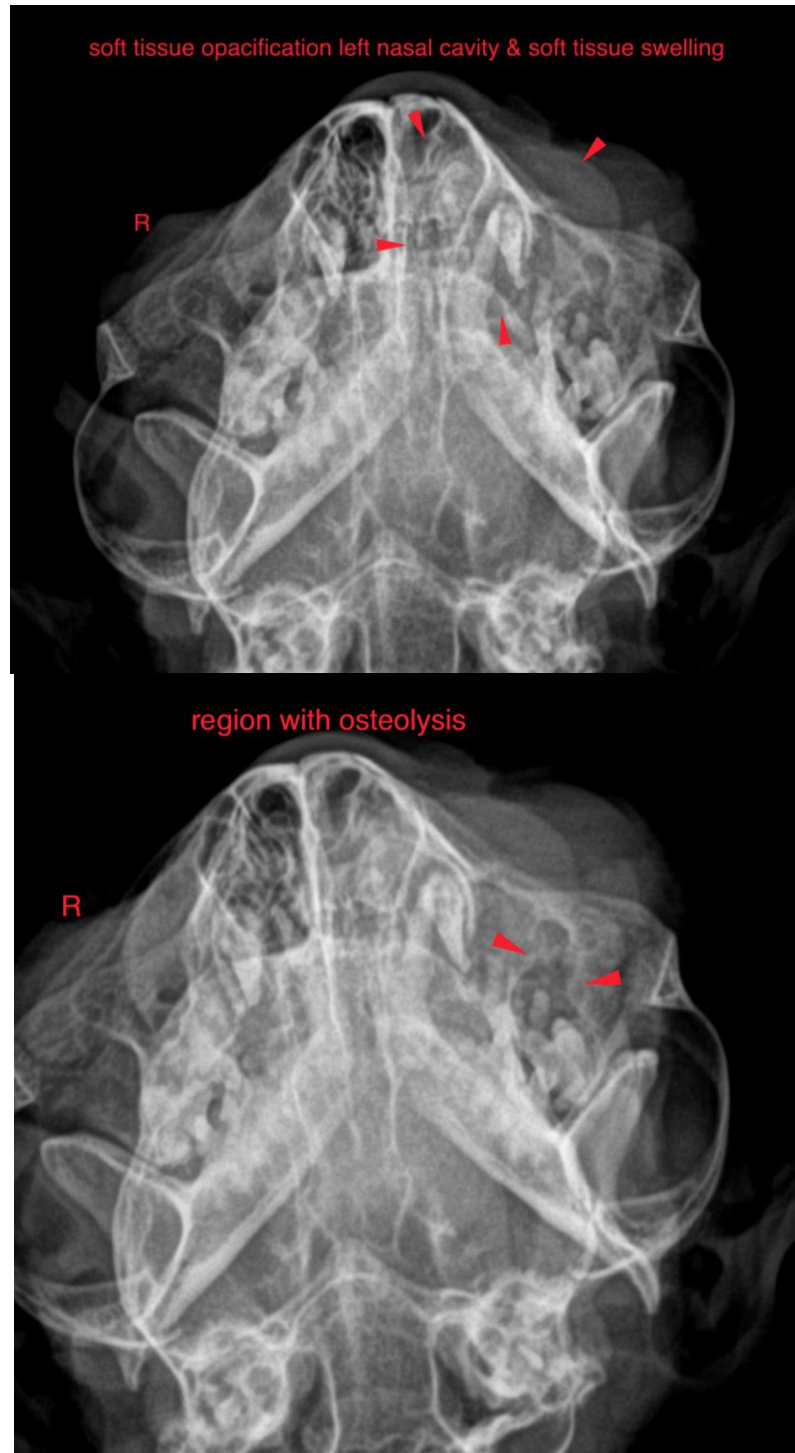
Dr. Medhat Meawad

INVOICE

53028

DATE

7-21-22





PATIENT

Vera Saddler

SPECIES

Feline

BREED

DSH

SEX

Spayed Female

AGE

14 Years

INTERPRETED BY

Sebastian Schaub, DVM
Dr. med. vet. DipECVDI

HOSPITAL NAME

Truscott Animal
Hospital

REFERRING VET

Dr. Medhat Meawad

INVOICE

53028

DATE

7-21-22

The information and recommendations provided are based on the images presented by the referring veterinarian/sonographer. No evaluation can be communicated regarding pathology that was not visible in the image/video clips provided.

Thank you for this referral. If the clinical or image interpretation does not parallel your findings or if I can be of any further assistance please contact me.

Sebastian Schaub, Sebastian Schaub, DVM, Dr. med. vet. DipECVDI
sebast.schaub@gmail.com