



PATIENT PRESENTING CLINICAL SIGNS

Lily Turner History: Washing machine type murmur noted very focally following premedication for spay. The murmur was not previously noted. The murmur is difficult to hear except very focally over the heart base area and is a grade 2/6 intensity when unmedicated, grade 4/6 undersedation. PDA is suspected.

SPECIES

Canine

Abnormal PE/Chem/CBC/UA Results:

RADIOGRAPHIC STUDY OF THE THORAX

BREED

Radiographs of the thorax in three imaging planes are provided for review.

Cavalier King Charles Spaniel

RADIOGRAPHIC FINDINGS

The surrounding bony structures are within normal limits.

SEX

The extrathoracic soft tissues present homogeneous without abnormalities.

Female

The heart is of normal size and shape, there is no evidence of cardiac chamber or vascular enlargement. The vertebral heart score is 10.2. The pulmonary vasculature is within normal limits.

AGE

6 Months

The cranial mediastinum presents the expected soft tissue opacity. The mediastinal width is less than twice the width of the vertebral column at the same level.

The trachea is normal in diameter and presents the anticipated course. The luminal outline of the trachea is smooth.

INTERPRETED BY

Sebastian Schaub,
DVM Dr. med. vet.
DipECVCI

The bronchial tree presents with thin walls and tapers uniformly towards the periphery as expected. The lung parenchyma presents the expected architecture and opacity; the intrapulmonary vascular branching is seen up to the third order lung vessels.

HOSPITAL NAME

Friendship Springs VC

The diaphragm is well delineated with even surface and the expected mild cranial bulging of the diaphragmatic cupola.

RADIOGRAPHIC DIAGNOSIS

REFERRING VET

Dr. Trae Cutchin

- Normal thorax

INTERPRETATION OF THE FINDINGS & FURTHER RECOMMENDATIONS

INVOICE

16730

The radiographic study of the thorax presents without abnormalities, no alterations of the cardiovascular structures are appreciated, there are no radiographic changes for PDA (e.g. ductal bump, pulmonary hyperperfusion, left atrial enlargement). Given the heart murmur, recommend complementing workup by a cardiac echo.

DATE

7/21/22



PATIENT

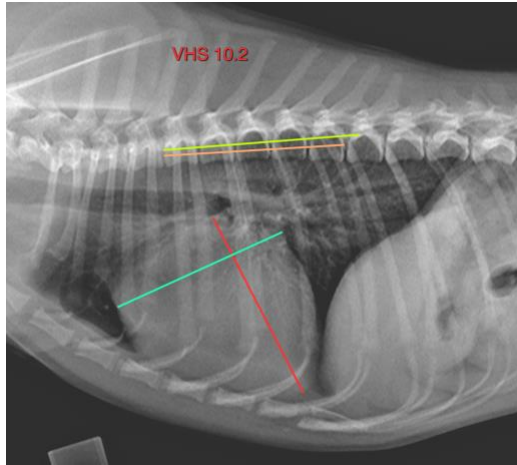
Lily Turner

SPECIES

Canine

BREED

Cavalier King Charles
Spaniel



SEX

Female

AGE

6 Months

The information and recommendations provided are based on the images presented by the referring veterinarian/sonographer. No evaluation can be communicated regarding pathology that was not visible in the image/video clips provided.

Thank you for this referral. If the clinical or image interpretation does not parallel your findings or if I can be of any further assistance please contact me.

Sebastian Schaub, Sebastian Schaub, DVM, Dr. med. vet. DipECVDI
sebast.schaub@gmail.com

INTERPRETED BY

Sebastian Schaub,
DVM Dr. med. vet.
DipECVDI

HOSPITAL NAME

Friendship Springs VC

REFERRING VET

Dr. Trae Cutchin

INVOICE

16730

DATE

7/21/22