



**PATIENT PRESENTING CLINICAL SIGNS**

Finny Szabo History: Asthma, hm , diabetes, constipations - chronic heavy breathing - harsh lung sounds on prednisolone low dose due to diabetes with flovent inhaler, on cisapride and mirlax on azithromycin qd 5 days then eod x 5 days

**SPECIES**

Abnormal PE/Chem/CBC/UA Results: harsh lung sounds

Feline

**RADIOGRAPHIC STUDY OF THE THORAX**

**BREED**

Radiographs of the thorax in two imaging planes are provided for review.

Tabby

**RADIOGRAPHIC FINDINGS**

The body condition score is 8/9.

**SEX**

Spayed Female

Moderate mineralization of the costal cartilage is seen, the costal cartilage of the caudal ribs present an s-shaped conformation.

**AGE**

13 Years

The extrathoracic soft tissues present homogeneous without abnormalities.

The heart is of normal size and shape, there is no evidence of cardiac chamber or vascular enlargement.

**INTERPRETED BY**

Sebastian Schaub,  
DVM Dr. med. vet.  
DipECVDI

The pulmonary vasculature is within normal limits.

The mediastinum is widened by fat.

The trachea is normal in diameter and presents the anticipated course. The luminal outline of the trachea is smooth.

**HOSPITAL NAME**

Legacy AH

Generalized mild to moderate peribronchial cuffing is appreciated.

The lung parenchyma presents the expected architecture and opacity; the intrapulmonary vascular branching is seen up to the third order lung vessels.

**REFERRING VET**

Dr. Kristin Potenzzone,  
DVM

The diaphragm is well delineated with even surface and the expected mild cranial bulging of the diaphragmatic cupola.

**RADIOGRAPHIC DIAGNOSIS**

**INVOICE**

16743

- Obesity
- Bronchial lung pattern without signs of air-trapping

**INTERPRETATION OF THE FINDINGS & FURTHER RECOMMENDATIONS**

**DATE**

7/21/22



**PATIENT**

Finny Szabo

The bronchial lung pattern is fitting the history of feline bronchial disease ('feline asthma') without signs of air-trapping. Superinfection may deteriorate clinical signs – e.g. bacterial, Mycoplasma, viral, parasitic.

**TECHNICAL COMMENTS**

**SPECIES**

Feline

Human fingers are seen in the primary beam, please consider radiation safety guidelines!

**BREED**

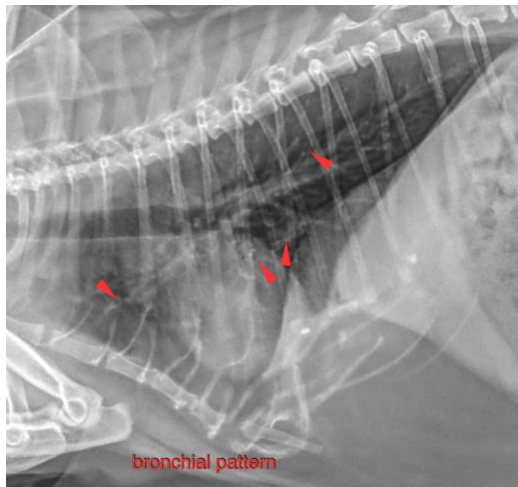
Tabby

**SEX**

Spayed Female

**AGE**

13 Years



**INTERPRETED BY**

Sebastian Schaub,  
DVM Dr. med. vet.  
DipECVDI

**The information and recommendations provided are based on the images presented by the referring veterinarian/sonographer. No evaluation can be communicated regarding pathology that was not visible in the image/video clips provided.**

Thank you for this referral. If the clinical or image interpretation does not parallel your findings or if I can be of any further assistance please contact me.

**HOSPITAL NAME**

Legacy AH

**Sebastian Schaub**, Sebastian Schaub, DVM, Dr. med. vet. DipECVDI  
sebast.schaub@gmail.com

**REFERRING VET**

Dr. Kristin Potenzzone,  
DVM

**INVOICE**

16743

**DATE**

7/21/22