



PATIENT PRESENTING CLINICAL SIGNS

Chloe Sheridan History: abnormal increased upper respiratory noises with nasal congestion
Abnormal PE/Chem/CBC/UA Results:

SPECIES COMPUTED TOMOGRAPHIC STUDY OF THE SKULL

Canine A high-resolution plain CT study of the skull is provided for review.

COMPUTED TOMOGRAPHIC FINDINGS

BREED

Chihuahua

Triadan 102, 103, 105, 107-109, 202, 203, 205-207, 209, 210, 305, 307, 311, 405, 407, 408 and 411 are absent. Triadan 106, 308 and 410 present a moderate widening of the periodontal space. The alveolar crest of triadan 104 is significantly widened and the root of triadan 104 is perforating the nasal cavity. Level with the root of triadan 104 perforating the nasal cavity, a moderate intranasal soft tissue swelling is appreciated. In both nasal cavities, a moderate amount of soft tissue attenuating material is attached to the conchal & turbinate structures, R>L. Moderate destruction of the right nasal conchal structures is seen.

SEX

Female

AGE

13 Years

Both temporomandibular joints present congruent joint spaces with even subchondral bone surfaces and are considered within normal limits.

Both tympanic bullae are aerated, the mucosal lining is not seen, the bony wall is smooth and thin. The external ear canals are within normal limits.

INTERPRETED BY

Sebastian Schaub,
DVM Dr. med. vet.
DipECVDI

The mandibular lymph nodes bilaterally are prominent.
The vertebral endplates C6/C7 present moderate spondylosis formation.

COMPUTED TOMOGRAPHIC DIAGNOSIS

HOSPITAL NAME

Animal Surgical
Center

- Advanced periodontal disease 104 with oronasal fistula formation and odontogenic destructive rhinitis
- Generalized periodontal disease of the remaining teeth, most accentuated 106, 308 and 410
- Mild lymphadenopathy mandibular lymph nodes
- Spondylosis deformans

REFERRING VET

Dr. Infernuso

INTERPRETATION OF THE FINDINGS & FURTHER RECOMMENDATIONS

INVOICE

16720

The CT study is consistent with periodontal abscess/granuloma formation triadan 104 with oronasal fistula formation and odontogenic rhinitis. The finding is a plausible explanation for the presenting clinical signs. If not done so yet, complete dental workup is recommended with extraction of the affected teeth. Biopsy of the alveolar crest of triadan 104 can be used to rule out underlying malignancy entirely.

Secondary reactive hyperplasia of the tributary mandibular lymph nodes.

DATE

7/21/22



PATIENT

Chloe Sheridan

SPECIES

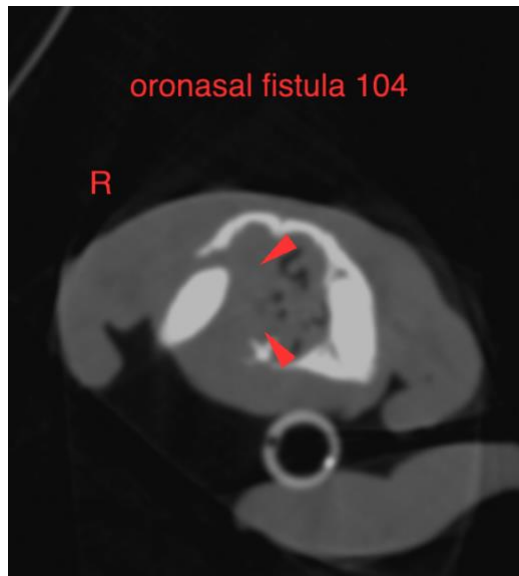
Canine

BREED

Chihuahua

SEX

Female



AGE

13 Years

The information and recommendations provided are based on the images presented by the referring veterinarian/sonographer. No evaluation can be communicated regarding pathology that was not visible in the image/video clips provided.

Thank you for this referral. If the clinical or image interpretation does not parallel your findings or if I can be of any further assistance please contact me.

INTERPRETED BY

Sebastian Schaub,
DVM Dr. med. vet.
DipECVDI

Sebastian Schaub, Sebastian Schaub, DVM, Dr. med. vet. DipECVDI
sebast.schaub@gmail.com

HOSPITAL NAME

Animal Surgical
Center

REFERRING VET

Dr. Infernuso

INVOICE

16720

DATE

7/21/22