



**PATIENT PRESENTING CLINICAL SIGNS**

Blue Sukhoruchkina History: Cat presented for dentistry. Owner noted cat coughs periodically?. Physical exam WNL. Heart/lungs auscultate WNL. Bloodwork all WNL. Radiographs of thorax taken for evaluation. Abnormal PE/Chem/CBC/UA Results:

**SPECIES RADIOGRAPHIC STUDY OF THE THORAX**

Feline Radiographs of the thorax in three imaging planes are provided for review.

**BREED RADIOGRAPHIC FINDINGS**

DSH The surrounding bony structures are within normal limits.  
The extrathoracic soft tissues present homogeneous without abnormalities.

**SEX**

Neutered Male The heart is of normal size and shape, there is no evidence of cardiac chamber or vascular enlargement. The pulmonary vasculature is within normal limits.

**AGE**

2 Years 2 Months The trachea is normal in diameter and presents the anticipated course. The luminal outline of the trachea is smooth.  
Multifocal mild peribronchial cuffing is appreciated.

**INTERPRETED BY**

The volume of the lung parenchyma is mildly decreased, accentuating a generalized mild unstructured reticular lung pattern.

Sebastian Schaub,  
DVM Dr. med. vet.  
DipECVDI

The diaphragm is well delineated with even surface and the expected mild cranial bulging of the diaphragmatic cupola.

**HOSPITAL NAME RADIOGRAPHIC DIAGNOSIS**

- Blairstown AH
- Mild bronchial pattern
  - No evidence of air-trapping
  - Mild hypoinflation of the lung parenchyma

**REFERRING VET**

Dr. Leal

**INTERPRETATION OF THE FINDINGS & FURTHER RECOMMENDATIONS**

The mild bronchial pattern in combination with the intermittent cough is suggestive for underlying feline bronchial disease ('feline asthma') without signs of air-trapping – although the bronchial pattern might be accentuated by the generalized mild hypoinflation of the lung parenchyma as well. There are no signs for active pneumonia.

**INVOICE**

16742

**DATE**

7/21/22



**PATIENT**

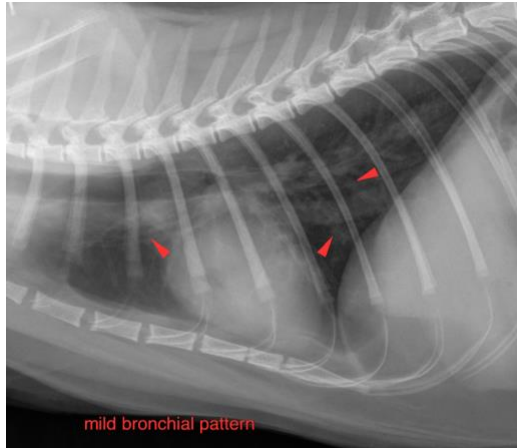
Blue Sukhoruchkina

**SPECIES**

Feline

**BREED**

DSH



**SEX**

Neutered Male

**AGE**

2 Years 2 Months

**The information and recommendations provided are based on the images presented by the referring veterinarian/sonographer. No evaluation can be communicated regarding pathology that was not visible in the image/video clips provided.**

Thank you for this referral. If the clinical or image interpretation does not parallel your findings or if I can be of any further assistance please contact me.

**Sebastian Schaub**, Sebastian Schaub, DVM, Dr. med. vet. DipECVDI  
sebast.schaub@gmail.com

**INTERPRETED BY**

Sebastian Schaub,  
DVM Dr. med. vet.  
DipECVDI

**HOSPITAL NAME**

Blairstown AH

**REFERRING VET**

Dr. Leal

**INVOICE**

16742

**DATE**

7/21/22