



PATIENT PRESENTING CLINICAL SIGNS

Rocky Adopt A Dog
Rescue

HISTORY OF DOG BITE WITHIN THE CERVICAL REGION, 4 MONTHS AGO

COMPUTED TOMOGRAPHIC STUDY OF THE NECK

SPECIES

Canine

A high-resolution plain CT study of the neck is provided for review.

COMPUTED TOMOGRAPHIC FINDINGS

The osseous and soft tissue structures of the neck are within normal limits, but mild central mineralization of multiple intervertebral discs along the cervical spine.

BREED

Maltipoo

The right scapula presents an irregular transverse fracture in the mid third with medial and caudal bending of the distal segment. The fracture is bridged by smooth mineralized callus formation.

Mild mineralization of the right superficial cervical lymph node and its tributary vessels is seen.

SEX

Neutered Male

COMPUTED TOMOGRAPHIC DIAGNOSIS

- Malunion after right mid scapular fracture
- Normal neck, but multifocal chondroid disc degeneration

AGE

2 Years

INTERPRETATION OF THE FINDINGS & FURTHER RECOMMENDATIONS

The CT study of the neck reveals no clinically relevant abnormality. There is a right scapular fracture that might be a source for right front limb lameness/gait abnormality. Depending on the presenting clinical signs and if there is suspicion for compressive myelopathy, recommend complementing workup by a post contrast CT study ± myelographic CT study of the cervical spine.

INTERPRETED BY

Sebastian Schaub,
DVM Dr. med. vet.
DipECVDD

HOSPITAL NAME

ASC-East Meadow

REFERRING VET

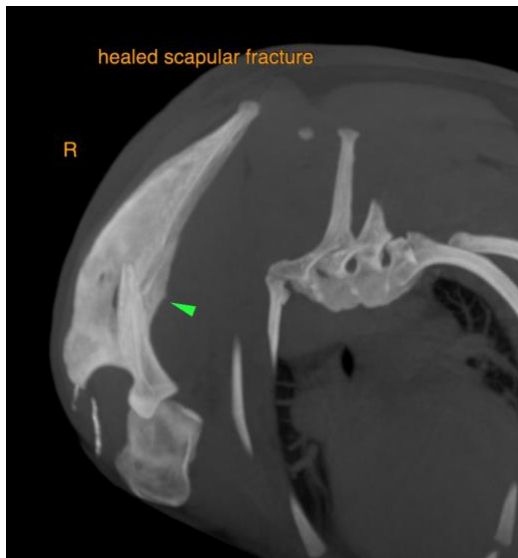
Rescue

INVOICE

23552

DATE

7/20/23





PATIENT

Rocky Adopt A Dog
Rescue

The information and recommendations provided are based on the images presented by the referring veterinarian/sonographer. No evaluation can be communicated regarding pathology that was not visible in the image/video clips provided.

Thank you for this referral. If the clinical or image interpretation does not parallel your findings or if I can be of any further assistance please contact me.

SPECIES

Canine

Sebastian Schaub, Sebastian Schaub, DVM, Dr. med. vet. DipECVDI
info@sonopath.com

BREED

Maltipoo

SEX

Neutered Male

AGE

2 Years

INTERPRETED BY

Sebastian Schaub,
DVM Dr. med. vet.
DipECVDI

HOSPITAL NAME

ASC-East Meadow

REFERRING VET

Rescue

INVOICE

23552

DATE

7/20/23