



PATIENT PRESENTING CLINICAL SIGNS

Maverick Jardon
History: For the past few months Maverick has started to get stiffer in his rear end. Yesterday he had a really hard time with the stairs. He is limping on the L hind. Sometimes he will use it sometimes he won't. He seems the most painful around his knee. He hasn't injured himself that Isaac knows of. He is still running and playing.

SPECIES

Canine
Abnormal PE/Chem/CBC/UA Results: Ambulatory X 4, LAMNESS LEFT HIND MEDIAL BUTRESS BOTH REAR DRAWER IN LEFT HIND

BREED RADIOGRAPHIC STUDY OF THE PELVIS AND STIFLE JOINTS

Rhodesian Ridgeback Mix
A complete set of radiographs of the pelvis & stifle joints is provided for review.

RADIOGRAPHIC FINDINGS

SEX
The osseous and surrounding soft tissue structures of the pelvis are within normal limits. Both coxofemoral joints present smooth osseous margins and congruent joint spaces.

Neutered Male

AGE

The periarticular bones of both stifle joints present mild to moderate osteophyte new bone formation and an intracapsular soft tissue swelling is distorting the infrapatellar fat pad cranially and the fascial plane caudally.

5 Years 8 Months

RADIOGRAPHIC DIAGNOSIS

INTERPRETED BY

- Degenerative osteoarthritis stifle joints bilaterally
- Articular swelling stifle joints bilaterally
- Normal pelvis & coxofemoral joints

Sebastian Schaub,
DVM Dr. med. vet.
DipECVDI

INTERPRETATION OF THE FINDINGS & FURTHER RECOMMENDATIONS

The radiographic study is consistent with bilateral chronic degenerative osteoarthritis with concomitant joint effusion of both stifle joints. The most-likely underlying cause is (partial) rupture of the cranial cruciate ligament with or without meniscal disease.

HOSPITAL NAME

Elizabeth AH

A positive drawer sign or tibial compression test under general anesthesia are confirming the diagnosis.

REFERRING VET

Kim Allyn, DVM

INVOICE

23584

DATE

7/20/23



PATIENT

Maverick Jardon

SPECIES

Canine

BREED

Rhodesian Ridgeback
Mix

SEX

Neutered Male

AGE

5 Years 8 Months

INTERPRETED BY

Sebastian Schaub,
DVM Dr. med. vet.
DipECVDI

HOSPITAL NAME

Elizabeth AH

REFERRING VET

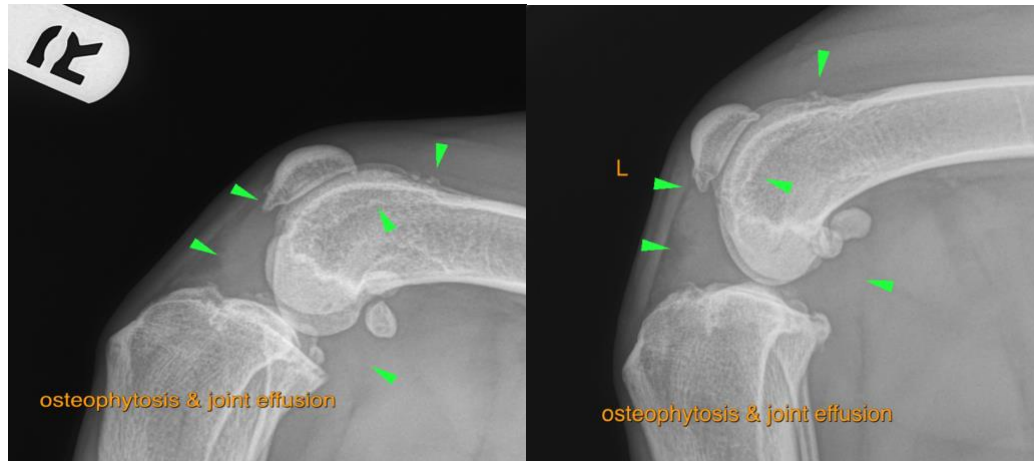
Kim Allyn, DVM

INVOICE

23584

DATE

7/20/23



The information and recommendations provided are based on the images presented by the referring veterinarian/sonographer. No evaluation can be communicated regarding pathology that was not visible in the image/video clips provided.

Thank you for this referral. If the clinical or image interpretation does not parallel your findings or if I can be of any further assistance please contact me.

Sebastian Schaub, Sebastian Schaub, DVM, Dr. med. vet. DipECVDI
info@sonopath.com