



PATIENT PRESENTING CLINICAL SIGNS

Lucky LaBrecue Patient has chronic eye infections per owner, came in on urgent care yesterday for a protruding left eye, owners stat they noticed 2 days ago.

SPECIES Abnormal PE/Chem/CBC/UA Results: Severe Conjunctivitis and Blepharitis of the Left Eye. Enucleation performed following CT as well as a neuter.

Feline

COMPUTED TOMOGRAPHIC STUDY OF THE SKULL

BREED A high resolution pre- and post-contrast CT study of the skull is provided for review.

DSH **COMPUTED TOMOGRAPHIC FINDINGS**

The crowns of triadan 101, 201 and 202 are absent.

SEX

Male The nasal cavity presents the expected aerated spaces between thin & even conchae and turbinates with smooth mucosal lining.

AGE

4 Years

The volume of the left ocular bulb is significantly increased, presenting an abnormal elongated ovoid shape, protruding rostrally beyond the osseous margins of the left orbital cavity. Multiple contrast enhancing lamella are protruding into the lumen of the left ocular bulb. The uvea is thickened. The lens of the left ocular bulb is subluxated into the vitreous chamber.

INTERPRETED BY

Both temporomandibular joints present congruent joint spaces with even subchondral bone surfaces and are considered within normal limits.

Sebastian Schaub,
DVM Dr. med. vet.
DipECVDI

Both tympanic bullae are aerated, the mucosal lining is not seen, the bony wall is smooth and thin. The external ear canals are within normal limits.

HOSPITAL NAME

Catskill VS, PLLC

The brain presents no deviation from normal anatomy and symmetry. The brain parenchyma is homogeneous and within normal limits for attenuation and distribution of contrast enhancement. The ventricular system is non-dilated and symmetric.

REFERRING VET

Dr. Lindsey Wright

The submandibular and medial retropharyngeal lymph nodes are small and elongated with a normal short-to-long-axis-ratio is < 0.5, the attenuation and contrast enhancement pattern is uniform.

COMPUTED TOMOGRAPHIC DIAGNOSIS

INVOICE

23587

- Left sided buphthalmos
- Left sided retinal detachment and uveal thickening
- Left sided posterior subluxation of the ocular lens
- Fractured crowns triadan 101, 201 and 202

INTERPRETATION OF THE FINDINGS & FURTHER RECOMMENDATIONS

DATE

7/20/23



PATIENT

Lucky LaBrecue

The changes of the left ocular bulb are suggestive to be secondary to glaucoma and there are signs for uveitis. Enucleation of the left ocular bulb has already been performed, regarding the history as indicated. Histopathology of the left ocular bulb should be considered to rule out malignant infiltrative disease.

SPECIES

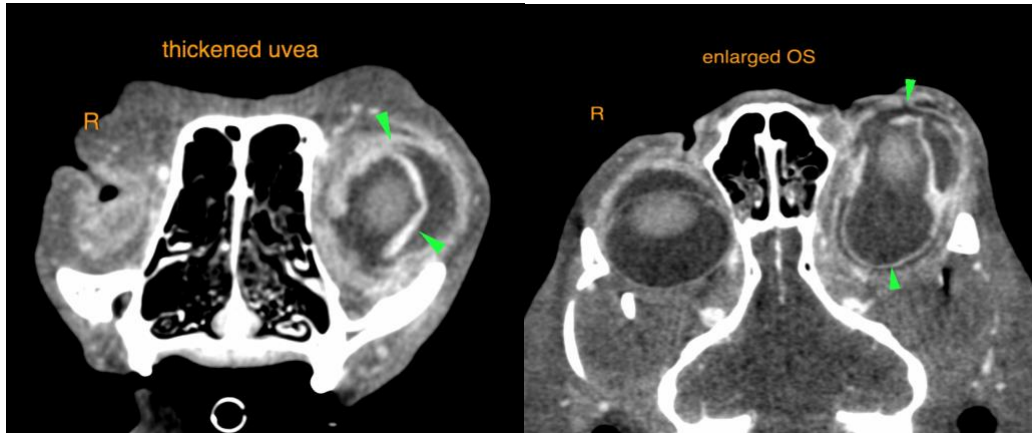
Feline

BREED

DSH

SEX

Male



AGE

4 Years

The information and recommendations provided are based on the images presented by the referring veterinarian/sonographer. No evaluation can be communicated regarding pathology that was not visible in the image/video clips provided.

Thank you for this referral. If the clinical or image interpretation does not parallel your findings or if I can be of any further assistance please contact me.

INTERPRETED BY

Sebastian Schaub,
DVM Dr. med. vet.
DipECVDI

Sebastian Schaub, Sebastian Schaub, DVM, Dr. med. vet. DipECVDI
info@sonopath.com

HOSPITAL NAME

Catskill VS, PLLC

REFERRING VET

Dr. Lindsey Wright

INVOICE

23587

DATE

7/20/23