



PATIENT PRESENTING CLINICAL SIGNS

Layla Chapman History: Separation Anxiety, Noise Phobia, Anaplasma, Grade 2/6 holosystolic murmur PMI left parasternum

SPECIES Abnormal PE/Chem/CBC/UA Results: Anaplasma

Canine **RADIOGRAPHIC STUDY OF THE THORAX**

Radiographs of the thorax in three imaging planes are provided for review.

BREED RADIOGRAPHIC FINDINGS

Golden Retriever Multifocal mild spondylosis formation is seen along the cranial segment of the thoracic spine.

The extrathoracic soft tissues present homogeneous without abnormalities.

SEX The heart is of normal size and shape, there is no evidence of cardiac chamber or vascular enlargement. The pulmonary vasculature is within normal limits.

Spayed Female

The cranial mediastinum presents the expected soft tissue opacity. The mediastinal width is less than twice the width of the vertebral column at the same level.

AGE The trachea is normal in diameter and presents the anticipated course. The luminal outline of the trachea is smooth.

11 Years

The bronchial tree presents with thin walls and tapers uniformly towards the periphery as expected.

INTERPRETED BY The lung parenchyma presents the expected architecture and opacity; the intrapulmonary vascular branching is seen up to the third order lung vessels.

Sebastian Schaub,
DVM Dr. med. vet.
DipECVDI

The diaphragm is well delineated with even surface and the expected mild cranial bulging of the diaphragmatic cupola.

HOSPITAL NAME RADIOGRAPHIC DIAGNOSIS

Williamsport West VH

- Spondylosis deformans
- Otherwise, normal thorax

REFERRING VET INTERPRETATION OF THE FINDINGS & FURTHER RECOMMENDATIONS

Stephanie A. Devario,
VMD

The radiographic study of the thorax presents without abnormalities. Workup of the heart murmur might be complemented by a cardiac echo for further assessment of cardiac chamber size and function.

INVOICE

23551

DATE

7/20/23



PATIENT

Layla Chapman

SPECIES

Canine

BREED

Golden Retriever

SEX

Spayed Female

AGE

11 Years

INTERPRETED BY

Sebastian Schaub,
DVM Dr. med. vet.
DipECVDI

HOSPITAL NAME

Williamsport West VH

REFERRING VET

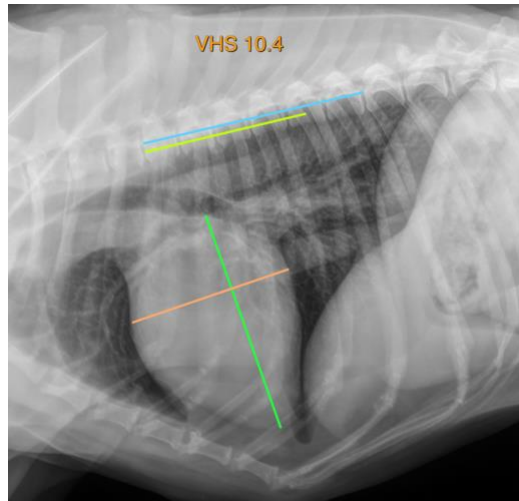
Stephanie A. Devario,
VMD

INVOICE

23551

DATE

7/20/23



The information and recommendations provided are based on the images presented by the referring veterinarian/sonographer. No evaluation can be communicated regarding pathology that was not visible in the image/video clips provided.

Thank you for this referral. If the clinical or image interpretation does not parallel your findings or if I can be of any further assistance please contact me.

Sebastian Schaub, Sebastian Schaub, DVM, Dr. med. vet. DipECVDI
info@sonopath.com