



PATIENT PRESENTING CLINICAL SIGNS

Otis Gawdunyk July 8,2022 a pea sized firm mass palpated on left anal sac 7 o'clock to rectum. All peripheral lymph nodes were normal. Cytology consistent with anal sac adenocarcinoma. CT for screening for staging and possible surgical planning.

SPECIES Abnormal PE/Chem/CBC/UA Results: Rectal examination: 1 cm mass/thickening left anal sac

Canine COMPUTED TOMOGRAPHY OF THE THORAX AND ABDOMEN

A pre- and post-contrast CT study of the thorax and abdomen in a bone, lung and soft tissue reon are provided for review.

BREED COMPUTED TOMOGRAPHIC FINDINGS

Labrador Thorax

The bony and surrounding soft tissue structures are within normal limits.

SEX The sternal, cranial mediastinal and tracheobronchial lymph nodes are small elongated with a normal short-to-long-axis-ratio is < 0.5, the attenuation and contrast enhancement pattern is uniform and considered within normal limits.

MN

The cardiovascular structures including the pulmonary vasculature are within normal limits.

AGE

5

A small amount of gas is encompassing the pulmonary artery of the left caudal lung lobe and is extending into the mediastinum.

INTERPRETED BY The lung parenchyma presents the expected architecture and attenuation behavior.

Sebastian Schaub, DVM Dr. med. vet. DipECVDI Small incidental gas pockets are seen within the esophageal lumen, there is no evidence of abnormal dilation.

Abdomen

HOSPITAL NAME The serosal fat presents normal attenuation behavior. There is no evidence of peritoneal effusion or peritonitis.

Animal Health Partners

Both kidneys present within normal limits for size, shape and organ architecture. After contrast administration a bilaterally symmetric and uniform nephro- and pyelogram is noted.

REFERRING VET The adrenal glands are within normal limits for size, shape and organ architecture.

Dr. J. Gagnon

The spleen presents with normal shape, even surface, uniformly attenuating parenchyma and homogeneous contrast enhancement, unremarkable.

INVOICE The right lateral liver lobe presents with a well-defined parenchymal filling defect, measuring 5 mm in size.

52980

The pancreas is evenly contoured, the pancreatic parenchyma is homogeneous and presents uniform contrast enhancement.

DATE

7-20-22

The position, delineation, wall and content of the gastrointestinal tract are considered within normal limits throughout.

In the medial aspect of the left anal sac, a moderate contrast enhancing nodular lesion, measuring 5 mm in diameter is appreciated.



PATIENT

The hypogastric lymph nodes are within normal limits.

Otis Gawdunyk

The bony and surrounding soft tissue structures reveal no abnormalities.

COMPUTED TOMOGRAPHIC DIAGNOSIS

SPECIES

Canine

- History of left sided anal sac adenocarcinoma
- Very mild pneumomediastinum with mild amount of gas along the broncho-vascular sheaths of the left caudal lung lobe
- No evidence of pulmonary metastatic disease

BREED

Labrador

INTERPRETATION OF THE FINDINGS & FURTHER RECOMMENDATIONS

The CT study is negative for metastatic disease of the diagnosed adenocarcinoma of the left anal sac.

SEX

MN

The mild pneumomediastinum is likely a sequela to general anesthesia with possible microtrauma to the lung parenchyma and gas dissecting along the broncho-vascular sheaths into the mediastinum (Macklin effect). This is considered an incidental finding and is commonly self-limiting.

AGE

5

INTERPRETED BY

Sebastian Schaub, DVM
Dr. med. vet. DipECVDI

HOSPITAL NAME

Animal Health
Partners

REFERRING VET

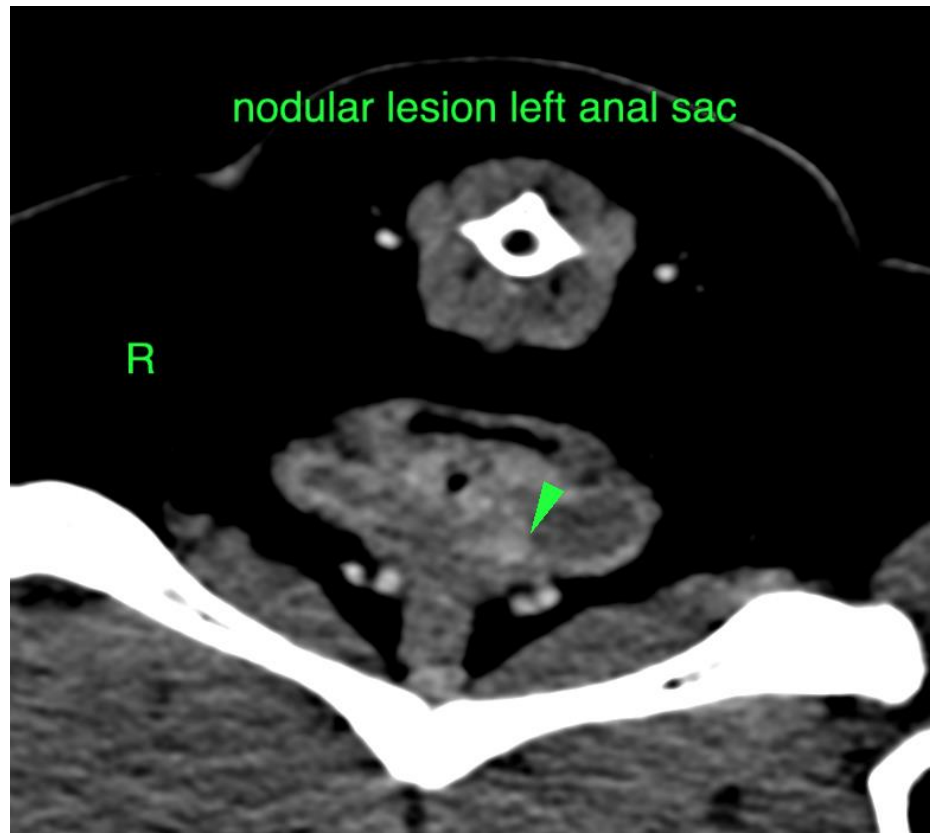
Dr. J. Gagnon

INVOICE

52980

DATE

7-20-22





PATIENT

Otis Gawdunyk

SPECIES

Canine

BREED

Labrador

SEX

MN

AGE

5

INTERPRETED BY

Sebastian Schaub, DVM
Dr. med. vet. DipECVDI

HOSPITAL NAME

Animal Health
Partners

REFERRING VET

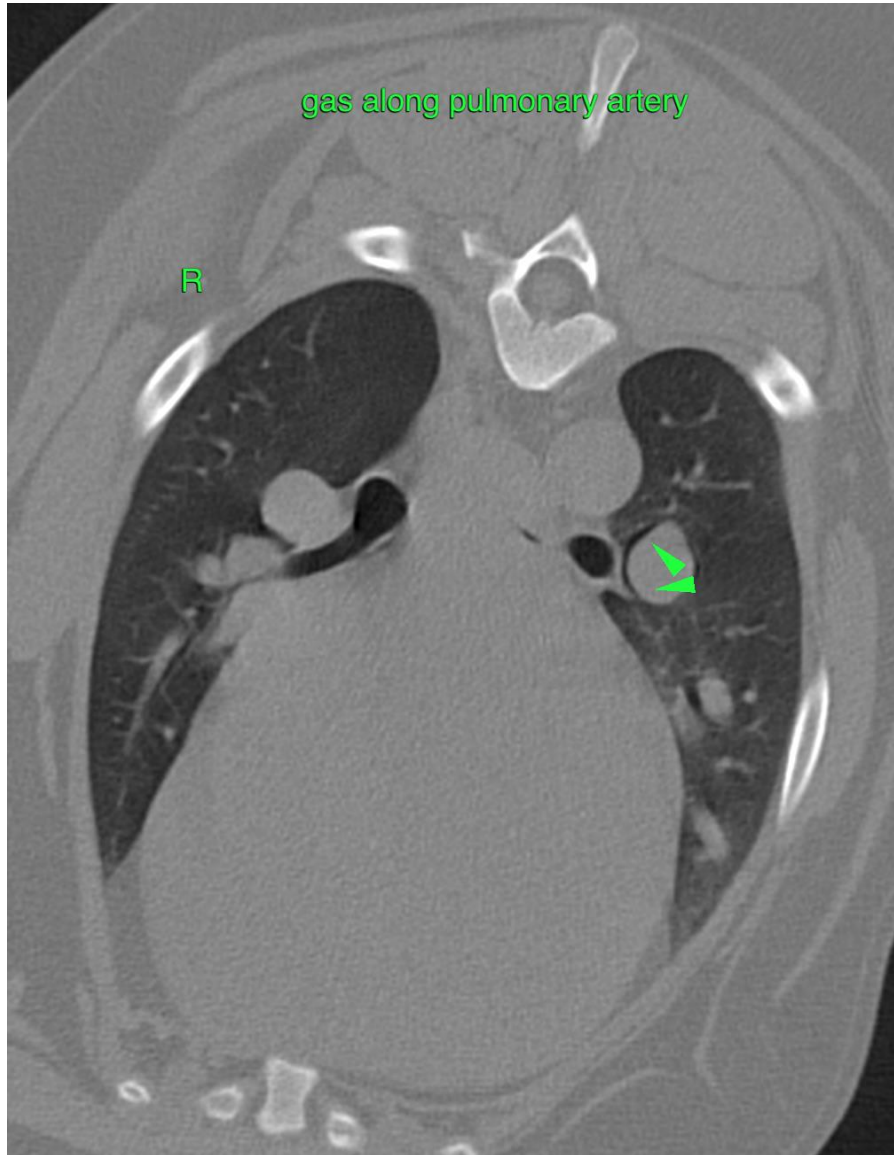
Dr. J. Gagnon

INVOICE

52980

DATE

7-20-22



The information and recommendations provided are based on the images presented by the referring veterinarian/sonographer. No evaluation can be communicated regarding pathology that was not visible in the image/video clips provided.

Thank you for this referral. If the clinical or image interpretation does not parallel your findings or if I can be of any further assistance please contact me.

Sebastian Schaub, Sebastian Schaub, DVM, Dr. med. vet. DipECVDI
sebast.schaub@gmail.com