



PATIENT

Nina Neumaier

PRESENTING CLINICAL SIGNS

Jumped off bed last night then was holding her leg up screaming. When Jim palpated it he heard felt it pop. It seems to be getting better though cause they saw her use it a couple times. Abnormal PE/Chem/CBC/UA Results: Medial luxation to left patella and uncomfortable at times with luxation.

SPECIES

Canine

RADIOGRAPHIC STUDY OF THE PELVIS AND STIFLE JOINTS

A ventrodorsal view of the pelvis and radiographs of the stifle joints in two orthogonal imaging planes are provided for review.

BREED

Pomeranian Mix

RADIOGRAPHIC FINDINGS

The VD projection of the pelvis is moderately rotated to the left. The osseous and surrounding soft tissue structures of the pelvis are within normal limits. Both coxofemoral joints present smooth osseous margins and congruent joint spaces.

SEX

Spayed

The patella of the left stifle joint is superimposed on the craniomedial aspect of the left femur.

Both stifle joint present smooth osseous margins. In comparison to the right stifle joint the left stifle joint presents mild intracapsular soft tissue swelling.

AGE

5 Years

RADIOGRAPHIC DIAGNOSIS

- Left sided medial patellar luxation
- Mild articular swelling left stifle joint
- Normal pelvis & coxofemoral joints

INTERPRETED BY

Sebastian Schaub, DVM
Dr. med. vet. DipECVDI

INTERPRETATION OF THE FINDINGS & FURTHER RECOMMENDATIONS

The findings are consistent with the history of medial patellar luxation of the left stifle joint. The mild joint effusion might be a sequela to the medial patellar luxation or in combination with the history is caused by traumatic insult ± pathology of the cranial cruciate ligament. If there is no history of medial patellar luxation, traumatic patellar luxation might be a potential as well. Rule out positive tibial compression test or drawer sign of the left stifle joint. Depending on the clinical findings and the history, a clinical trial with NSAID and rest might be beneficial and reevaluating the patient in 2 weeks.

HOSPITAL NAME

Elizabeth Animal Hospital

REFERRING VET

Kim Allyn, DVM

INVOICE

52993

DATE

7-20-22



PATIENT

Nina Neumaier

SPECIES

Canine

BREED

Pomeranian Mix

SEX

Spayed

AGE

5 Years

INTERPRETED BY

Sebastian Schaub, DVM
Dr. med. vet. DipECVDI

HOSPITAL NAME

Elizabeth Animal
Hospital

REFERRING VET

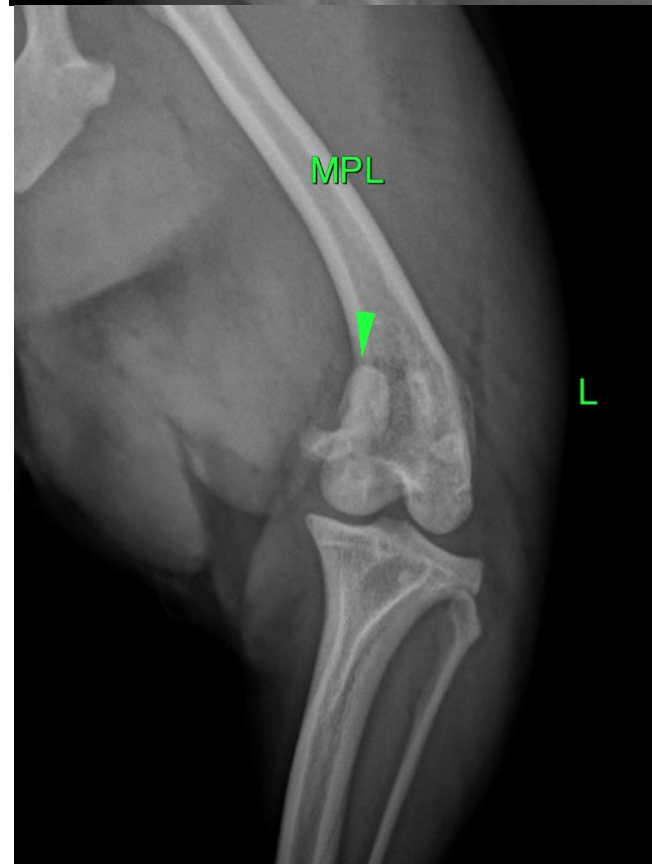
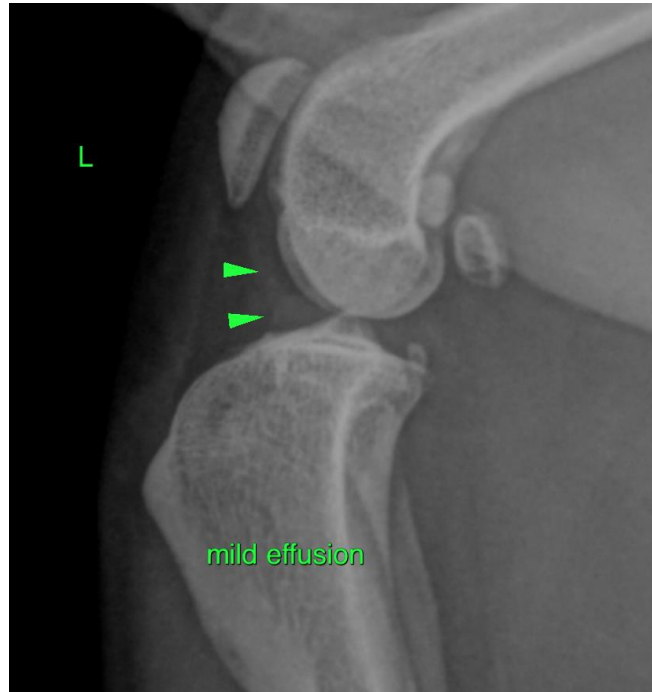Kim Allyn, DVM

INVOICE

52993

DATE

7-20-22





PATIENT

Nina Neumaier

SPECIES

Canine

The information and recommendations provided are based on the images presented by the referring veterinarian/sonographer. No evaluation can be communicated regarding pathology that was not visible in the image/video clips provided.

BREED

Pomeranian Mix

Thank you for this referral. If the clinical or image interpretation does not parallel your findings or if I can be of any further assistance please contact me.

Sebastian Schaub, Sebastian Schaub, DVM, Dr. med. vet. DipECVDI
sebast.schaub@gmail.com

SEX

Spayed

AGE

5 Years

INTERPRETED BY

Sebastian Schaub, DVM
Dr. med. vet. DipECVDI

HOSPITAL NAME

Elizabeth Animal
Hospital

REFERRING VET

Kim Allyn, DVM

INVOICE

52993

DATE

7-20-22