



**PATIENT**

Moose Fillipi

**PRESENTING CLINICAL SIGNS**

Lameness on right forelimb. No response to medications. Ongoing for 4 weeks.

**SPECIES**

Canine

**COMPUTED TOMOGRAPHY OF THE FRONT LIMBS**

A high resolution pre- and post-contrast CT study of the front limbs is provided for review.

**BREED**

Cane Corso

**COMPUTED TOMOGRAPHIC FINDINGS**

The shoulder joints are cropped by the field of view.

The periarticular bones of the left elbow joint present mild osteophyte new bone formation. The medial coronoid process of both elbow joints is irregular marginated and present a heterogeneous density with sclerosis.

**SEX**

Male Intact

- Coronoid pathology elbow joints bilaterally
- Very mild degenerative osteoarthritis right elbow joint

**COMPUTED TOMOGRAPHIC DIAGNOSIS**

**AGE**

7 Months

**INTERPRETATION OF THE FINDINGS & FURTHER RECOMMENDATIONS**

The findings are consistent with bilateral fragmented medial coronoid process with signs of mild degenerative joint disease of the right elbow joint. Due to mild motion artefacts, thin fissure lines might be missed.

Arthroscopy is recommended to revise the elbow joint(s). Overall prognosis for the patient to be free of lameness is considered good after fragment removal. However, episodes of lameness may reoccur after exercise.

**INTERPRETED BY**

Sebastian Schaub, DVM  
Dr. med. vet. DipECVDI

**HOSPITAL NAME**

Animal Medical  
Center of Mt.  
Pleasant

**REFERRING VET**

Steven Epstein, DVM

**INVOICE**

53006

**DATE**

7-20-22



**PATIENT**

Moose Fillipi

**SPECIES**

Canine

**BREED**

Cane Corso

**SEX**

Male Intact

**AGE**

7 Months

**INTERPRETED BY**

Sebastian Schaub, DVM  
Dr. med. vet. DipECVDI

**HOSPITAL NAME**

Animal Medical  
Center of Mt.  
Pleasant

**REFERRING VET**

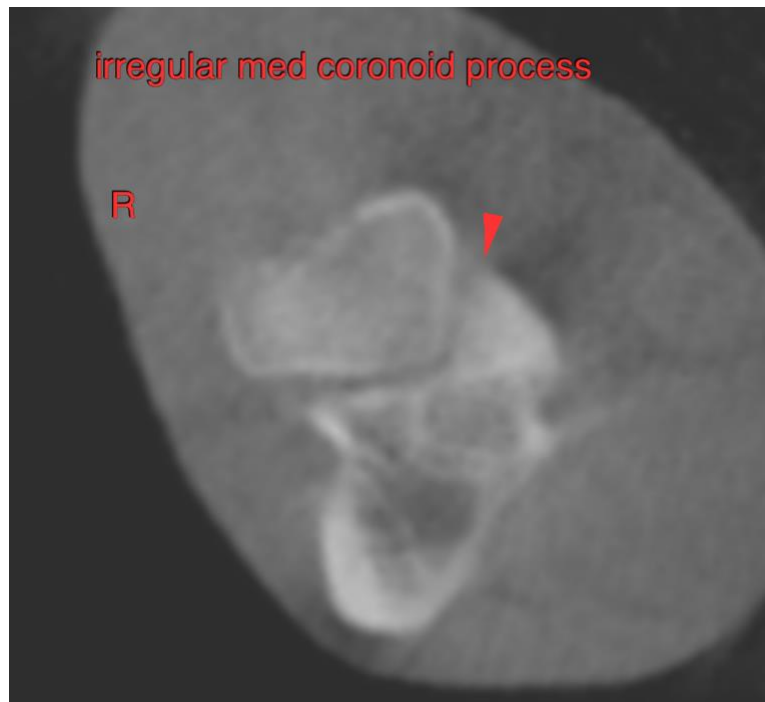
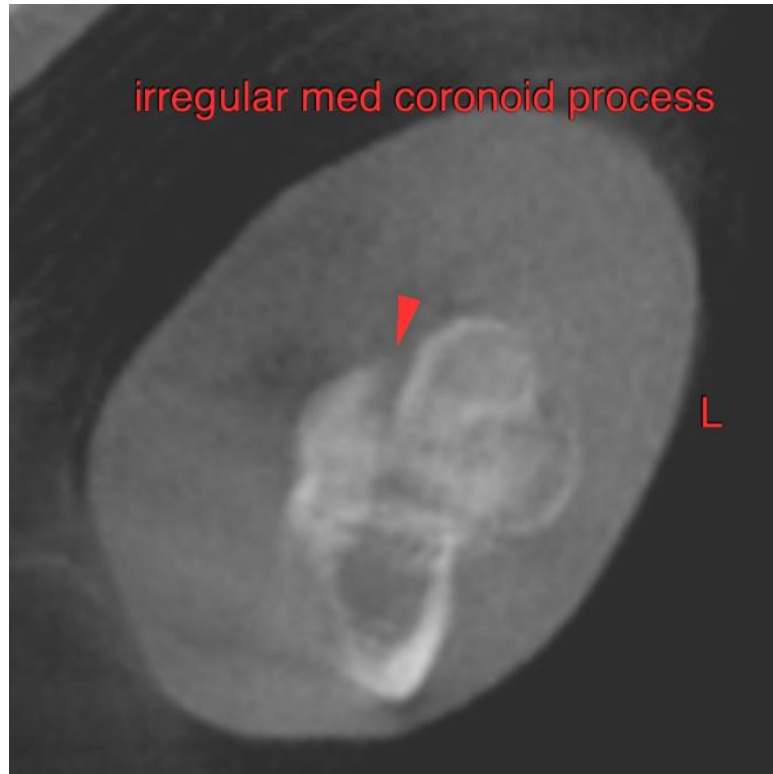
Steven Epstein, DVM

**INVOICE**

53006

**DATE**

7-20-22





**PATIENT**

Moose Fillipi

The information and recommendations provided are based on the images presented by the referring veterinarian/sonographer. No evaluation can be communicated regarding pathology that was not visible in the image/video clips provided.

**SPECIES**

Canine

Thank you for this referral. If the clinical or image interpretation does not parallel your findings or if I can be of any further assistance please contact me.

**BREED**

Cane Corso

**Sebastian Schaub**, Sebastian Schaub, DVM, Dr. med. vet. DipECVDI  
sebast.schaub@gmail.com

**SEX**

Male Intact

**AGE**

7 Months

**INTERPRETED BY**

Sebastian Schaub, DVM  
Dr. med. vet. DipECVDI

**HOSPITAL NAME**

Animal Medical  
Center of Mt.  
Pleasant

**REFERRING VET**

Steven Epstein, DVM

**INVOICE**

53006

**DATE**

7-20-22