

**PATIENT PRESENTING CLINICAL SIGNS**

Chevy Welteroth Pt has had lameness in left rear leg since August of 2019, suspected partial or full tear of CCL. Has in the past been toe touching on left rear leg and holding it up. Owner said that pt has a hard time getting up after laying down for a while. Left stifle has thickening and crepitus. While anesthetized for CT, definite cranial drawer sign left stifle, possible drawer sign right stifle.

SPECIES

Canine

COMPUTED TOMOGRAPHY OF THE STIFLE JOINTS

A high resolution pre- and post-contrast CT study of the stifle joints is provided for review.

BREED COMPUTED TOMOGRAPHIC FINDINGS

Labrador Retriever

The periarticular bones of both stifle joints moderate osteophyte new bone formation, L>>R. Post contrast administration the left stifle joint presents a thickened synovial lining and moderate intracapsular soft tissue swelling; the infrapatellar fat-pad cranially and the fascial plane caudally are compressed. The right stifle joint presents mild intracapsular soft tissue swelling and mild prominent synovial capsule.

SEX

Neutered Male

COMPUTED TOMOGRAPHIC DIAGNOSIS

- Degenerative osteoarthritis stifle joints bilaterally, L>>R
- Articular swelling stifle joints bilaterally, L>>R
- Synovialitis, L>>R

AGE

7 Years

INTERPRETED BY INTERPRETATION OF THE FINDINGS & FURTHER RECOMMENDATIONS

Sebastian Schaub, DVM
Dr. med. vet. DipECVDI

The appreciated degenerative joint disease and joint effusion of both stifle joints, L>>R, in combination with the positive drawer sign (L>>R), is considered as a sequela to pathology of the cranial cruciate ligament ± meniscal pathology. The CT study presents no signs of aggressive bone lesion or gastrocnemius enthesopathy.

HOSPITAL NAME

Williamsport West
Veterinary Hospital

REFERRING VET

Stephanie Daverio,
VMD

INVOICE

59468

DATE

7-19-23



PATIENT

Chevy Welteroth

SPECIES

Canine

BREED

Labrador Retriever

SEX

Neutered Male

AGE

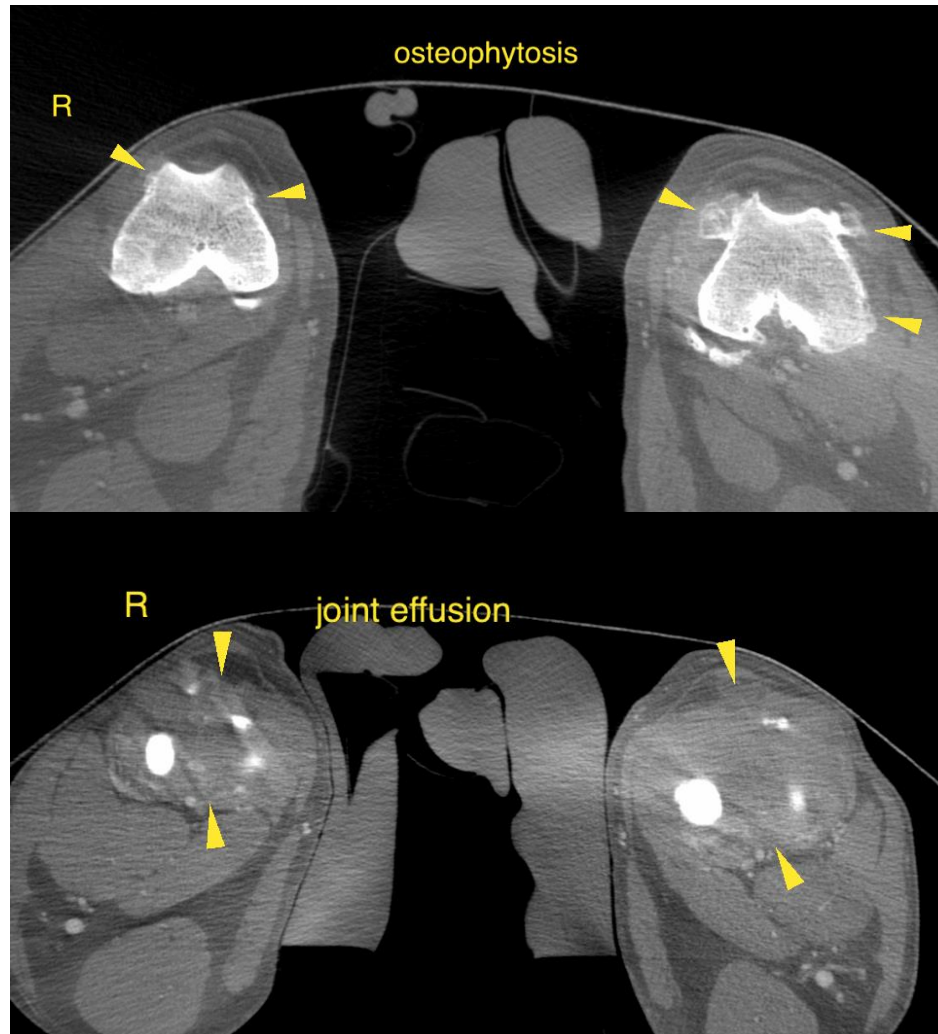
7 Years

INTERPRETED BY

Sebastian Schaub, DVM
Dr. med. vet. DipECVDI

HOSPITAL NAME

Williamsport West
Veterinary Hospital



REFERRING VET

Stephanie Daverio,
VMD

The information and recommendations provided are based on the images presented by the referring veterinarian/sonographer. No evaluation can be communicated regarding pathology that was not visible in the image/video clips provided.

Thank you for this referral. If the clinical or image interpretation does not parallel your findings or if I can be of any further assistance please contact me.

INVOICE

59468

Sebastian Schaub, Sebastian Schaub, DVM, Dr. med. vet. DipECVDI
info@sonopath.com

DATE

7-19-23