

**PATIENT PRESENTING CLINICAL SIGNS**

Stewy Fox *DVM pet. Sneezing blood for about 3-6 months. Dental procedure done in april. Symptoms worsen recently.

SPECIES COMPUTED TOMOGRAPHY OF THE SKULL

Feline A high resolution pre- and post-contrast CT study of the skull is provided for review.

COMPUTED TOMOGRAPHIC FINDINGS

Triadan 203 is absent.

BREED

DSH

The left nasal cavity is filled with soft tissue material mild peripheral contrast enhancement. Moderate destruction of the associated conchal & turbinate structures is appreciated. The cribriform plate presents with moth-eaten osteolytic lesions and is perforated in the ventral aspect. In the left rostral cranial fossa, very mild heterogeneous contrast enhancing material is visible, and the falx cerebri is deviated to the right and the olfactory bulb caudally by the mass effect.

SEX

Neutered Male

Both temporomandibular joints present congruent joint spaces with even subchondral bone surfaces and are considered within normal limits.

AGE

14 Years

Both tympanic bullae are aerated, the mucosal lining is not seen, the bony wall is smooth and thin. The external ear canals are within normal limits.

The submandibular and medial retropharyngeal lymph nodes are small and elongated with a normal short-to-long-axis-ratio is < 0.5, the attenuation and contrast enhancement pattern is uniform.

INTERPRETED BY

Sebastian Schaub, DVM
Dr. med. vet. DipECVDI

COMPUTED TOMOGRAPHIC DIAGNOSIS

- Left sided biologically aggressive nasal soft tissue mass with invasion of the cranial fossa
- Absent triadan 203

HOSPITAL NAME

Mobile Pet Imaging

INTERPRETATION OF THE FINDINGS & FURTHER RECOMMENDATIONS

The findings are consistent with a biologically aggressive nasal soft tissue mass, dissecting through the cribriform plate into the cranial fossa with mass effect on the brain. Differentials include lymphosarcoma, adenocarcinoma, squamous cell carcinoma, transitional cell carcinoma, other. Rhinoscopy including biopsy can be used as advanced diagnostic tests.

REFERRING VET

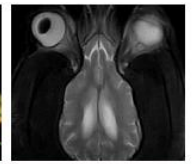
Meaux

INVOICE

52953

DATE

7-19-22



PATIENT

Stewy Fox

SPECIES

Feline

BREED

DSH

SEX

Neutered Male

AGE

14 Years

INTERPRETED BY

Sebastian Schaub, DVM
Dr. med. vet. DipECVDI

HOSPITAL NAME

Mobile Pet Imaging

REFERRING VET

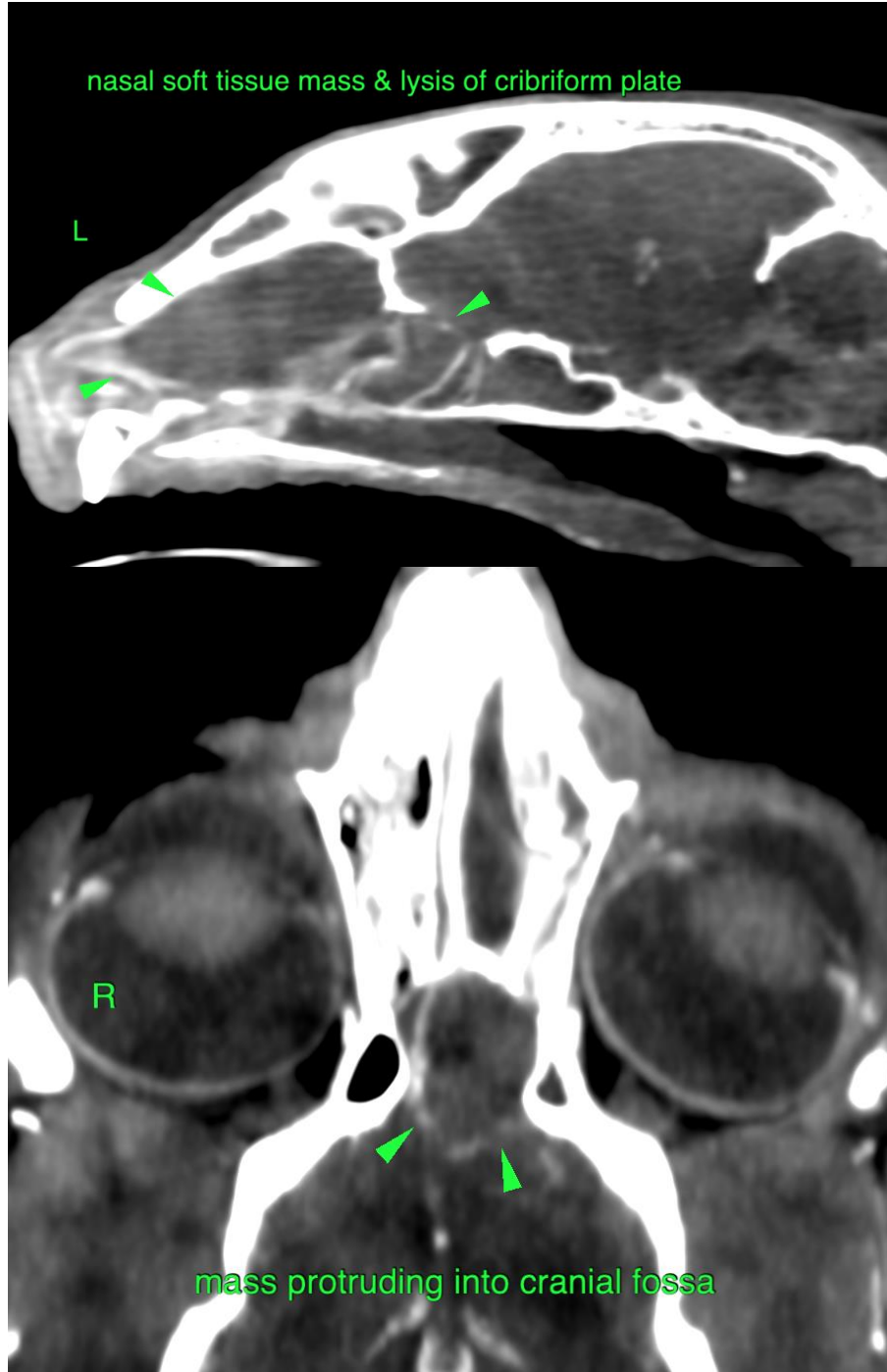
Meaux

INVOICE

52953

DATE

7-19-22





PATIENT

Stewy Fox

The information and recommendations provided are based on the images presented by the referring veterinarian/sonographer. No evaluation can be communicated regarding pathology that was not visible in the image/video clips provided.

SPECIES

Feline

Thank you for this referral. If the clinical or image interpretation does not parallel your findings or if I can be of any further assistance please contact me.

Sebastian Schaub, Sebastian Schaub, DVM, Dr. med. vet. DipECVDI
sebast.schaub@gmail.com

BREED

DSH

SEX

Neutered Male

AGE

14 Years

INTERPRETED BY

Sebastian Schaub, DVM
Dr. med. vet. DipECVDI

HOSPITAL NAME

Mobile Pet Imaging

REFERRING VET

Meaux

INVOICE

52953

DATE

7-19-22