



PATIENT

Charlie Tolentino-Cooke

PRESENTING CLINICAL SIGNS

Vomiting for the last few days, once or twice a day after eating grass. Owner said today, he is hacking more than normal.

SPECIES

Canine

RADIOGRAPHIC STUDY OF THE THORAX & ABDOMEN

Radiographs of the thorax and abdomen in three imaging planes are provided for review.

BREED

Miniature Poodle

RADIOGRAPHIC FINDINGS

Thorax

The surrounding bony structures are within normal limits, the growth plates are age related open.

The extrathoracic soft tissues present homogeneous without abnormalities.

The heart is of normal size and shape, there is no evidence of cardiac chamber or vascular enlargement. The pulmonary vasculature is within normal limits.

SEX

Spayed Female

The cranial mediastinum presents the expected soft tissue opacity. The mediastinal width is less than twice the width of the vertebral column at the same level.

AGE

10 Months

The trachea is normal in diameter and presents the anticipated course. The luminal outline of the trachea is smooth.

The bronchial tree presents with thin walls and tapers uniformly towards the periphery as expected.

INTERPRETED BY

Sebastian Schaub, DVM
Dr. med. vet. DipECVDI

The lung parenchyma presents the expected architecture and opacity; the intrapulmonary vascular branching is seen up to the third order lung vessels.

The diaphragm is well delineated with even surface and the expected mild cranial bulging of the diaphragmatic cupola.

HOSPITAL NAME

Truscott Animal Hospital

Abdomen

The surrounding bony structures are within normal limits.

No abnormalities of the extraabdominal soft tissues are noted. The abdominal wall is smooth and thin.

REFERRING VET

Dr. Medhat Meawad

The serosal detail is maintained throughout the peritoneal and retroperitoneal space.

The liver is appropriate in position, size and presents uniform opacity.

INVOICE

52977

The splenic head is in the anticipated position and within normal limits for size and opacity. The splenic body and tail are considered normal for position, size, shape and opacity.

Both kidneys are seen and present with normal size, shape, delineation and opacity. The urinary bladder is in its anticipated position. No radiopaque calculi are noted throughout the upper and lower urinary tract.

DATE

7-19-22

The stomach is in its anticipated position and is empty but a very small amount of foamy material.



PATIENT

Charlie Tolentino-
Cooke

There is a small intestinal loop in the right abdomen, mild to moderate distended by gas – ending level with the ascending colon, suggestive for the ileum. Some small intestinal loops contain foamy material without pathological dilation.

The colon is seen in the expected position and presents with appropriate content.

SPECIES

Canine

RADIOGRAPHIC DIAGNOSIS

- Suspect gas distended ileum and alimentary pattern of some small intestinal segments
- Normal thorax

BREED

Miniature Poodle

INTERPRETATION OF THE FINDINGS & FURTHER RECOMMENDATIONS

The material in the small intestinal loops is considered as chymus and there is no evidence of pathological dilation of the small intestinal loops. There are no signs for gastrointestinal mechanical obstruction or radiopaque foreign material. The presumptive diagnosis for the intermittent vomiting is gastritis. If clinical signs are refractory to empirical therapy, recommend follow up radiographs or a complete abdominal ultrasound examination.

SEX

Spayed Female

The radiographic study of the thorax presents without abnormalities, there is no sign for pneumonia or bronchitis. However, negative radiographs do not rule out tracheitis or bronchitis entirely and radiographic changes can lack behind clinical signs. Rule out upper airway inflammation for the presenting clinical signs as well.

AGE

10 Months

INTERPRETED BY

Sebastian Schaub, DVM
Dr. med. vet. DipECVDI

HOSPITAL NAME

Truscott Animal
Hospital

REFERRING VET

Dr. Medhat Meawad

INVOICE

52977

DATE

7-19-22



PATIENT

Charlie Tolentino-Cooke

SPECIES

Canine

BREED

Miniature Poodle

SEX

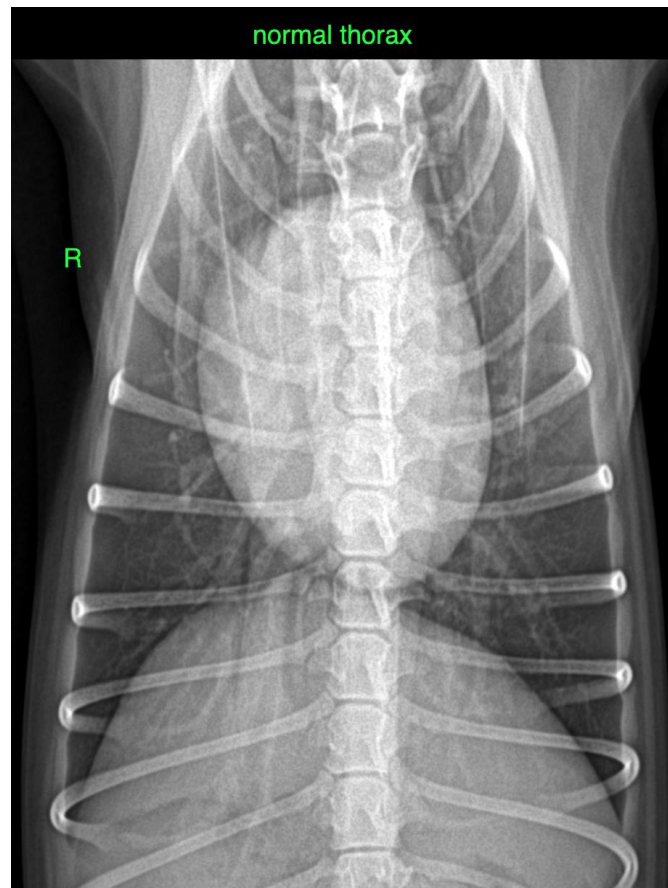Spayed Female

AGE

10 Months

INTERPRETED BY

Sebastian Schaub, DVM
Dr. med. vet. DipECVDI



HOSPITAL NAME

Truscott Animal Hospital

REFERRING VET

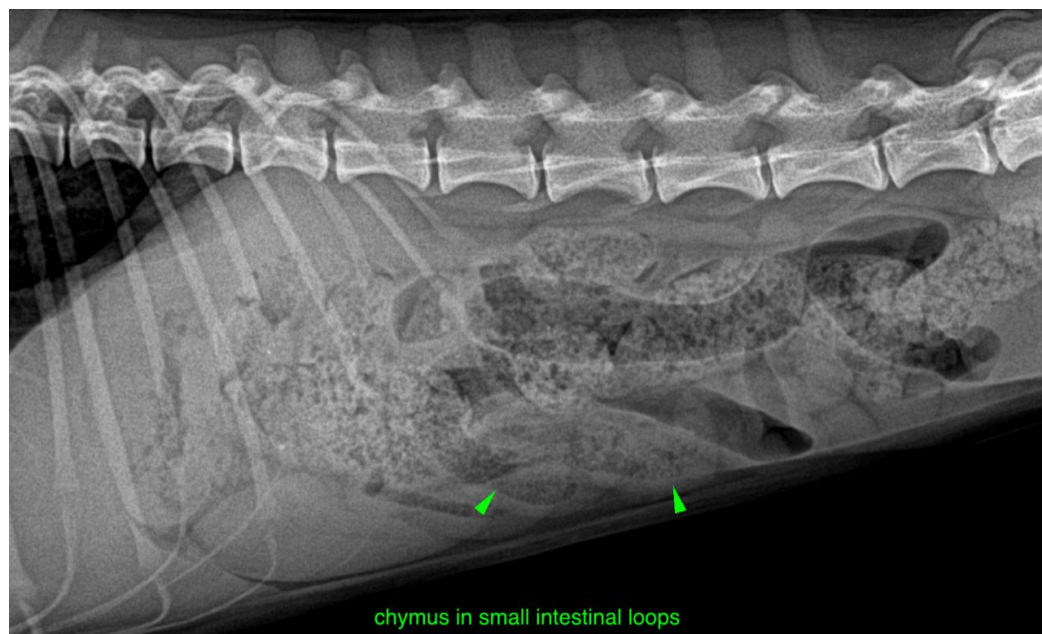
Dr. Medhat Meawad

INVOICE

52977

DATE

7-19-22





PATIENT

Charlie Tolentino-Cooke

SPECIES

Canine

BREED

Miniature Poodle

SEX

Spayed Female

AGE

10 Months

INTERPRETED BY

Sebastian Schaub, DVM
Dr. med. vet. DipECVDI

HOSPITAL NAME

Truscott Animal
Hospital

REFERRING VET

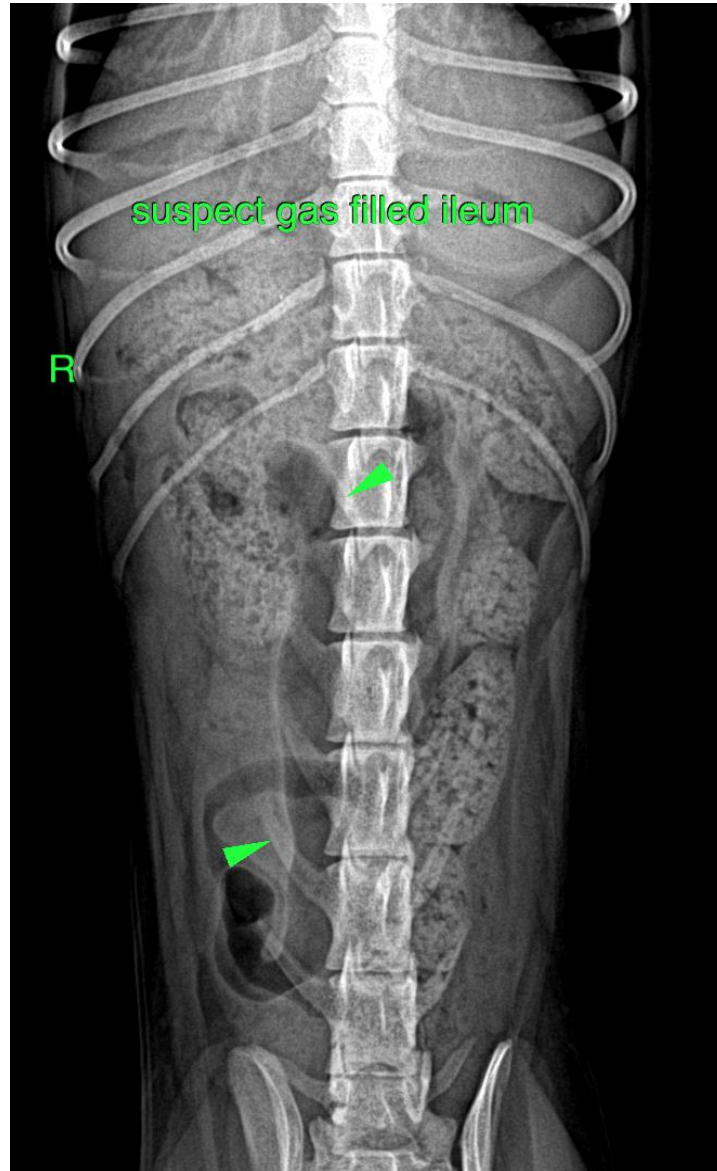
Dr. Medhat Meawad

INVOICE

52977

DATE

7-19-22



The information and recommendations provided are based on the images presented by the referring veterinarian/sonographer. No evaluation can be communicated regarding pathology that was not visible in the image/video clips provided.

Thank you for this referral. If the clinical or image interpretation does not parallel your findings or if I can be of any further assistance please contact me.

Sebastian Schaub, Sebastian Schaub, DVM, Dr. med. vet. DipECVDI
sebast.schaub@gmail.com