



**PATIENT**

Charli Sandney

**PRESENTING CLINICAL SIGNS**

7 Yo Golden retriever with a 2 weeks history of left thoracic lameness (improving) and difficulty getting up. Examination revealed discomfort on left elbow and shoulder palpation (mild in both) and LS pain. Previous X-rays report (read by radiologist) revealed a questionable lucency on left humerus. CT-scan to assess elbows and rule out osteosarcoma on the shoulder" :

**SPECIES**

Canine

**COMPUTED TOMOGRAPHY OF THE FRONT LIMBS**

A plain CT study of the front limbs in a bone and soft tissue reconstruction is provided for review.

**BREED**

Golden Retriever

**COMPUTED TOMOGRAPHIC FINDINGS**

At the distal aspect of the acromion of the right scapular, a well-defined, ovoid shaped isolated mineral attenuating body is visible. The fat in the left axillary region presents a mild soft tissue striation, not appreciated in the contralateral limb. The remainder of the osseous and surrounding soft tissue structures of the shoulder joints are within normal limits.

**SEX**

FS

The periarticular bones of the right elbow joint present mild osteophyte new bone formation. The medial coronoid process of the right elbow joint is well-defined and presents a homogeneous density.

**AGE**

7

The periarticular bones of the left elbow joint present smooth osseous margins, the medial coronoid process is well-defined, unremarkable.

**COMPUTED TOMOGRAPHIC DIAGNOSIS**

- Mild swelling of the fat in the left axillary region
- Mild degenerative osteoarthritis right elbow joint
- Isolated ossification center distal aspect of the acromion of the right scapula

**INTERPRETED BY**

Sebastian Schaub, DVM  
Dr. med. vet. DipECVDI

**HOSPITAL NAME**

Animal Health Partners

**INTERPRETATION OF THE FINDINGS & FURTHER RECOMMENDATIONS**

There is evidence of mild steatitis of the fat in the left axillary region and preceding trauma with hematoma or primary inflammatory process are considerations here and might be a source for the described clinical signs. Check if pain can be elicited by deep palpation of the left axillary region.

**REFERRING VET**

Dr. Hugo Leonard

The mild degenerative osteoarthritis of the right elbow joint might be a sequela to 'wear-and-tear' as there is no history of lameness of the right front limb or signs for overt elbow dysplasia.

**INVOICE**

52949

**DATE**

7-19-22



**PATIENT**

Charli Sandney

**SPECIES**

Canine

**BREED**

Golden Retriever

**SEX**

FS

**AGE**

7

**INTERPRETED BY**

Sebastian Schaub, DVM  
Dr. med. vet. DipECVDI

**HOSPITAL NAME**

Animal Health  
Partners

**REFERRING VET**

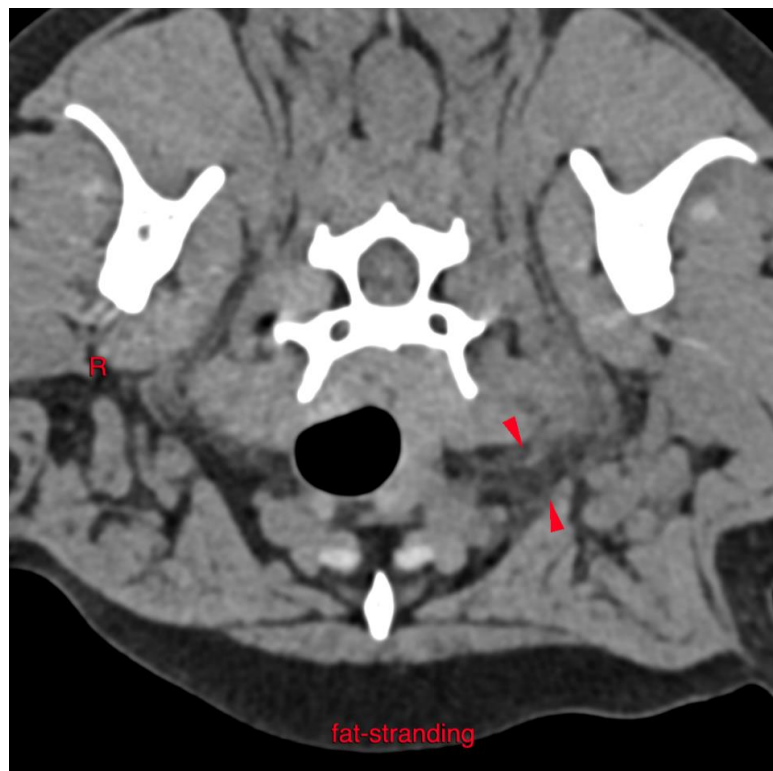
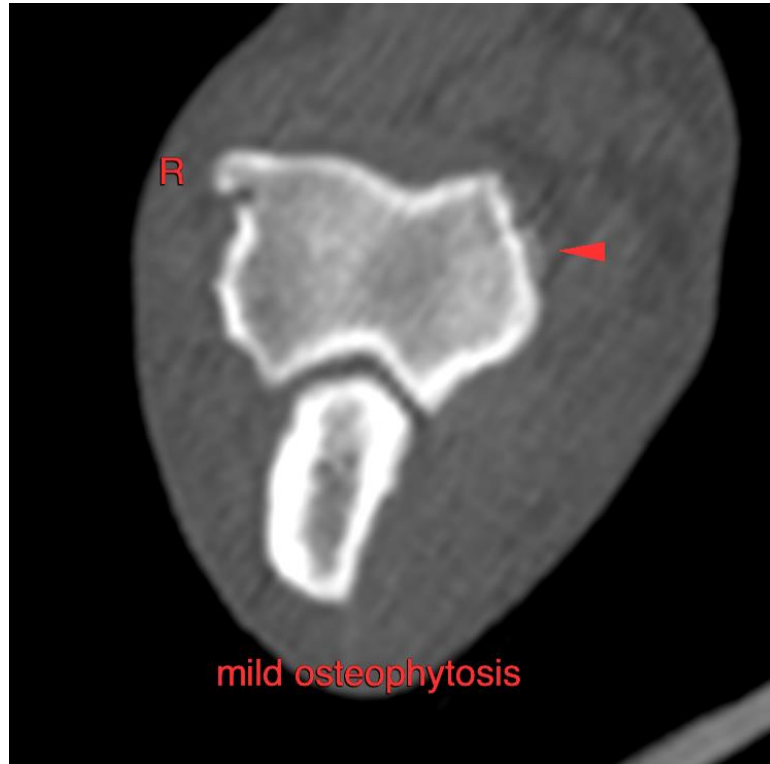
Dr. Hugo Leonard

**INVOICE**

52949

**DATE**

7-19-22





**PATIENT**

Charli Sandney

**SPECIES**

Canine

The information and recommendations provided are based on the images presented by the referring veterinarian/sonographer. No evaluation can be communicated regarding pathology that was not visible in the image/video clips provided.

**BREED**

Golden Retriever

Thank you for this referral. If the clinical or image interpretation does not parallel your findings or if I can be of any further assistance please contact me.

**Sebastian Schaub**, Sebastian Schaub, DVM, Dr. med. vet. DipECVDI  
sebast.schaub@gmail.com

**SEX**

FS

**AGE**

7

**INTERPRETED BY**

Sebastian Schaub, DVM  
Dr. med. vet. DipECVDI

**HOSPITAL NAME**

Animal Health  
Partners

**REFERRING VET**

Dr. Hugo Leonard

**INVOICE**

52949

**DATE**

7-19-22