



PATIENT PRESENTING CLINICAL SIGNS

Coco Bright Hx of polyp left ear canal. Symptoms have recurred. Surgeon requesting pre-op imaging.

COMPUTED TOMOGRAPHY OF THE SKULL

SPECIES A high resolution pre- and post-contrast CT study of the skull is provided for review.

Feline **COMPUTED TOMOGRAPHIC FINDINGS**

Multiple teeth are absent.

BREED The nasal cavity presents the expected aerated spaces between thin & even conchae and turbinates with smooth mucosal lining.

Domestic Short Hair

Both temporomandibular joints present congruent joint spaces with even subchondral bone surfaces and are considered within normal limits.

SEX A defect is seen in the ventral aspect of the thickened wall of the left tympanic bulla. The left tympanic bulla is partially filled with fluid attenuating material. The external ear canals are within normal limits.
FS The right tympanic bulla is aerated and presents a thin osseous lining.

AGE The brain presents no deviation from normal anatomy and symmetry. The brain parenchyma is homogeneous and within normal limits for attenuation and distribution of contrast enhancement. The ventricular system is non-dilated and symmetric.

12 Years

The medial retropharyngeal lymph nodes are prominent.

INTERPRETED BY

COMPUTED TOMOGRAPHIC DIAGNOSIS

Sebastian Schaub, DVM
Dr. med. vet. DipECVDI

- History of left sided ventral bulla osteotomy due to chronic otitis media
- Lymphadenopathy medial retropharyngeal lymph nodes
- Multiple absent teeth

HOSPITAL NAME

Paws and Claws
Urgent Care

INTERPRETATION OF THE FINDINGS & FURTHER RECOMMENDATIONS

There is no evidence of reoccurrence of an inflammatory polyp, but the left sided otitis media – the changes can still present normal state post ventral bulla osteotomy. Myringotomy might be used to flush the left tympanic bulla and check for possible infectious agents.

REFERRING VET

Alexis Rambaud

INVOICE

59437

DATE

7-18-23



PATIENT

Coco Bright

SPECIES

Feline

BREED

Domestic Short Hair

SEX

FS

AGE

12 Years

INTERPRETED BY

Sebastian Schaub, DVM
Dr. med. vet. DipECVDI

HOSPITAL NAME

Paws and Claws
Urgent Care

REFERRING VET

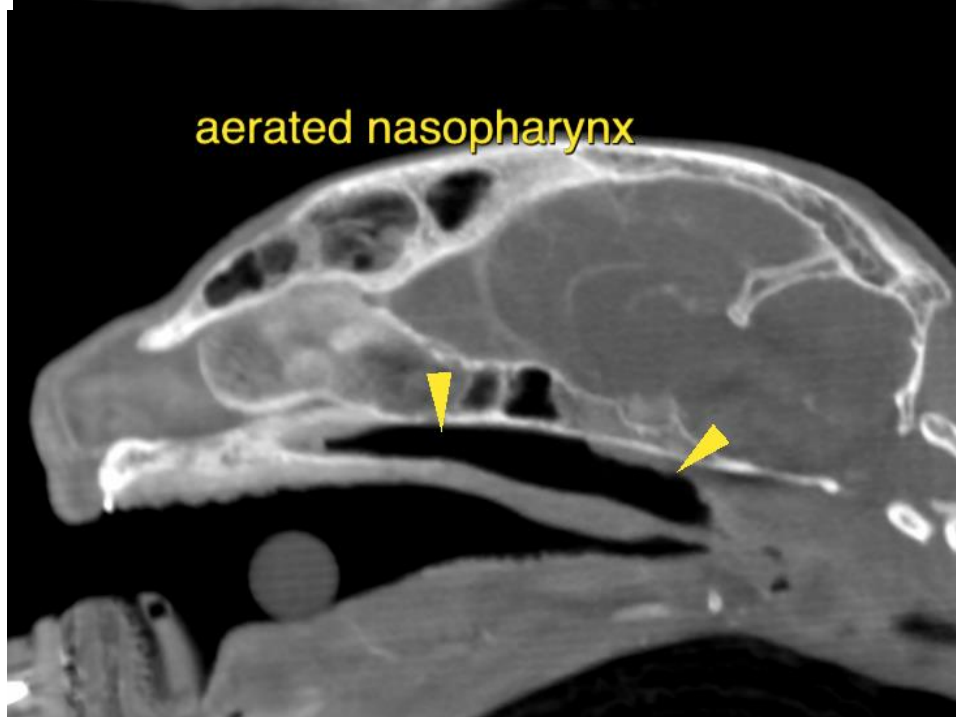
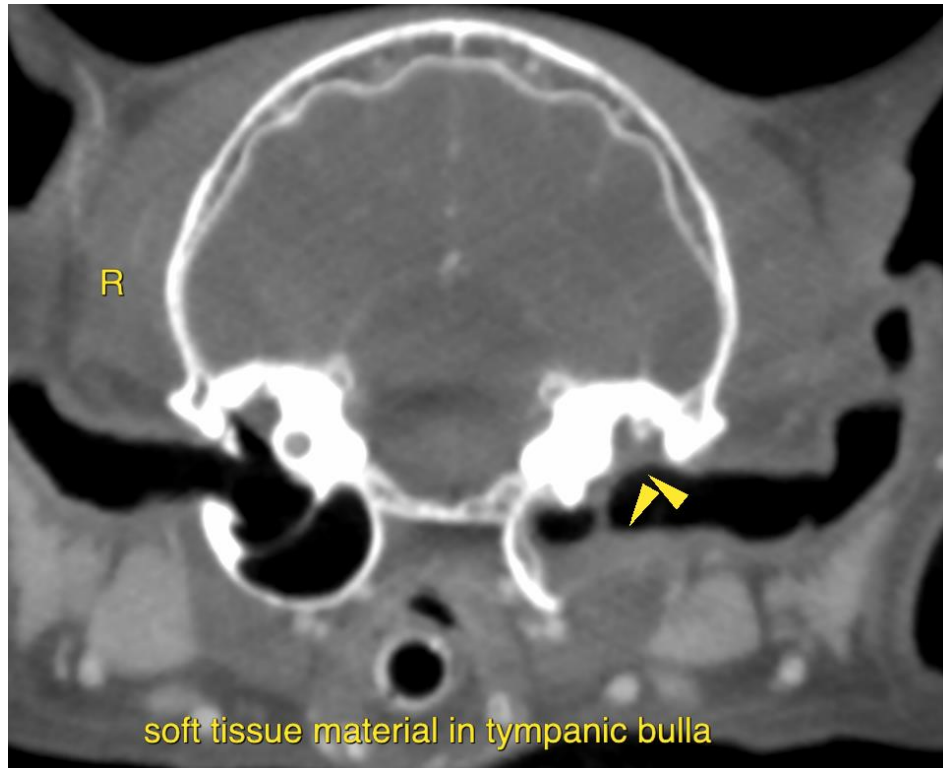
Alexis Rambaud

INVOICE

59437

DATE

7-18-23





PATIENT

Coco Bright

The information and recommendations provided are based on the images presented by the referring veterinarian/sonographer. No evaluation can be communicated regarding pathology that was not visible in the image/video clips provided.

SPECIES

Feline

Thank you for this referral. If the clinical or image interpretation does not parallel your findings or if I can be of any further assistance please contact me.

BREED

Domestic Short Hair

Sebastian Schaub, Sebastian Schaub, DVM, Dr. med. vet. DipECVDI
info@sonopath.com

SEX

FS

AGE

12 Years

INTERPRETED BY

Sebastian Schaub, DVM
Dr. med. vet. DipECVDI

HOSPITAL NAME

Paws and Claws
Urgent Care

REFERRING VET

Alexis Rambaud

INVOICE

59437

DATE

7-18-23