



**PATIENT PRESENTING CLINICAL SIGNS**

Poochie Creehan Evaluate dentition

**COMPUTED TOMOGRAPHY OF THE SKULL**

**SPECIES** A high resolution plain CT study of the skull is provided for review.

Canine **COMPUTED TOMOGRAPHIC FINDINGS**

**BREED**

Yorkshire Terrier

Triadan 106, 206, 210, 305, 306, 311, 405 and 411 are absent. A small fragment of a root of triadan 106 is noted – the periodontal space is thin and unremarkable. Triadan 109, 110, 209 and 410 present a widened periodontal space. Triadan 403 presents periapical widened periodontal space and perforation of the cortex ventrally. Triadan 205 presents a resorptive lesion.

The nasal cavity presents the expected aerated spaces between thin & even conchae and turbinates with smooth mucosal lining.

**SEX**

MC

Both temporomandibular joints present congruent joint spaces with even subchondral bone surfaces and are considered within normal limits.

**COMPUTED TOMOGRAPHIC DIAGNOSIS**

**AGE**

12 Years

- Periodontal disease 109, 110, 209 and 410
- Periapical abscess 403
- Tooth root resorption 205
- Multiple absent teeth, see above

**INTERPRETED BY**

Sebastian Schaub, DVM  
Dr. med. vet. DipECVDI

**INTERPRETATION OF THE FINDINGS & FURTHER RECOMMENDATIONS**

Multiple teeth present signs of advanced periodontal disease including root abscess of triadan 403; if not done so yet, extraction of the respective teeth is considered beneficial.

**HOSPITAL NAME**

Cranberry Holistic  
Pet Care

**REFERRING VET**

Cynthia Maro

**INVOICE**

59384

**DATE**

7-17-23



**PATIENT**

Poochie Creehan

**SPECIES**

Canine

**BREED**

Yorkshire Terrier

**SEX**

MC

**AGE**

12 Years

**INTERPRETED BY**

Sebastian Schaub, DVM  
Dr. med. vet. DipECVDI

**HOSPITAL NAME**

Cranberry Holistic  
Pet Care

**REFERRING VET**

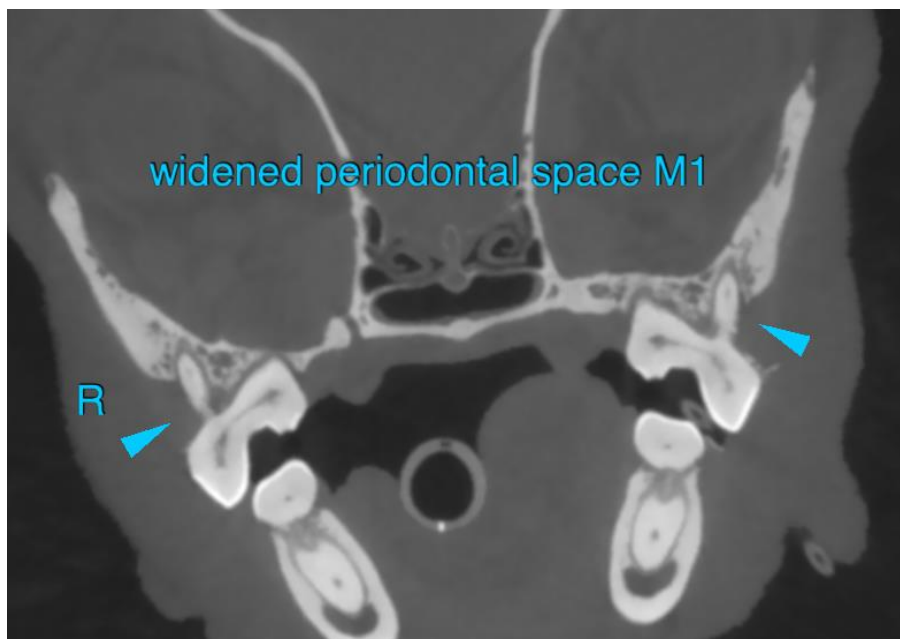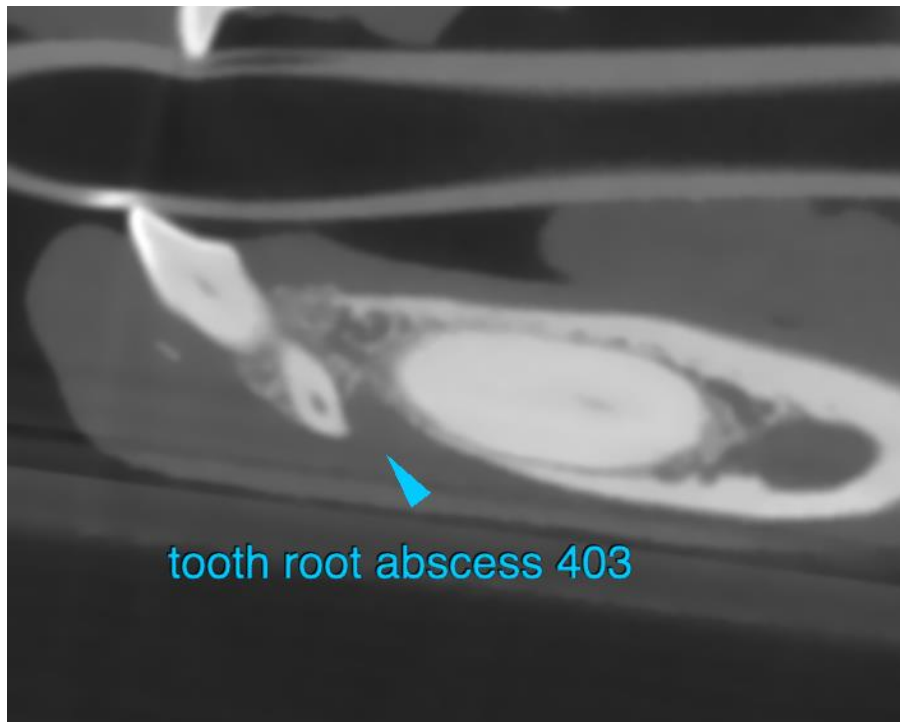Cynthia Maro

**INVOICE**

59384

**DATE**

7-17-23





**PATIENT**

Poochie Creehan

**SPECIES**

Canine

**BREED**

Yorkshire Terrier

**SEX**

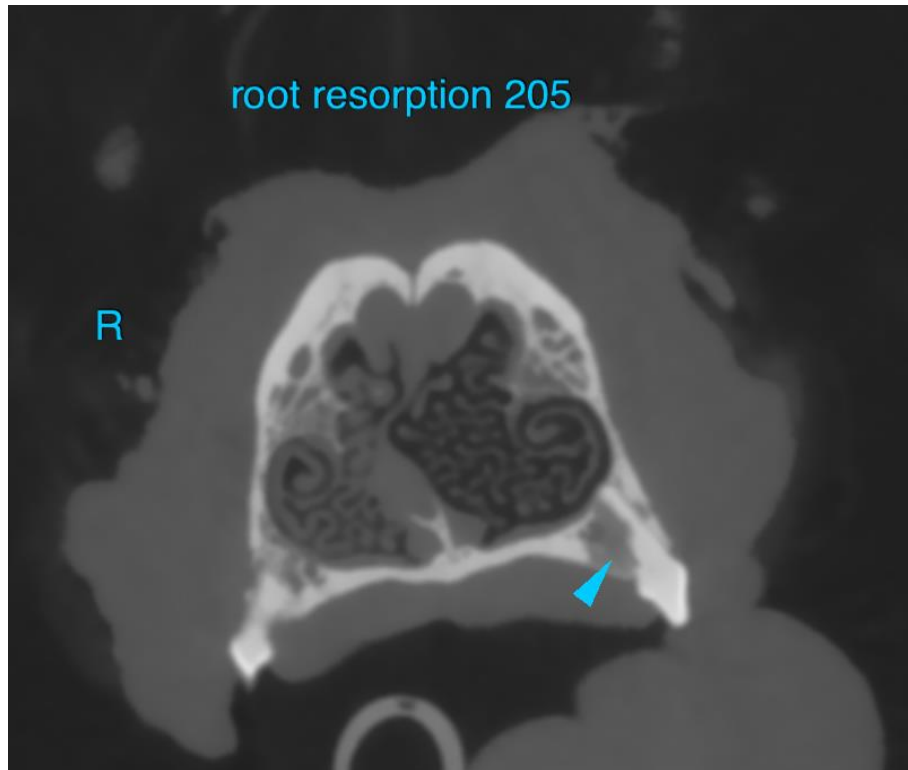
MC

**AGE**

12 Years

**INTERPRETED BY**

Sebastian Schaub, DVM  
Dr. med. vet. DipECVDI



**HOSPITAL NAME**

Cranberry Holistic  
Pet Care

The information and recommendations provided are based on the images presented by the referring veterinarian/sonographer. No evaluation can be communicated regarding pathology that was not visible in the image/video clips provided.

Thank you for this referral. If the clinical or image interpretation does not parallel your findings or if I can be of any further assistance please contact me.

**REFERRING VET**

Cynthia Maro

**Sebastian Schaub**, Sebastian Schaub, DVM, Dr. med. vet. DipECVDI  
[info@sonopath.com](mailto:info@sonopath.com)

**INVOICE**

59384

**DATE**

7-17-23