

**PATIENT PRESENTING CLINICAL SIGNS**

Helen Coccodrilli P was referred from RDVM for CT. P was playing normally on 4th of July with another dog, then that Friday P began to slow down. That Saturday P began to limp on the RH. P has been walking around with a limp since, has progressed to knuckling on both hind legs. P was put on antibiotic and steroid by RDVM but no improvement has been seen so far, started ~4 days ago. Performed a myelogram today.

**SPECIES**

Canine

**COMPUTED TOMOGRAPHY OF THE THORACIC & LUMBAR SPINE**

A high pre- and post-contrast and myelographic CT study of the thoracic & lumbar spine is provided for review.

**BREED**

Irish Setter

**COMPUTED TOMOGRAPHIC FINDINGS**

Level with T13/L1, mild hyperattenuating material is seen in the epidural space, effacing the margins of the dural tube at the same level.

**SEX**

FS

After intrathecal contrast administration, the contrast column is extending along the epidural space, resulting in an irregular shape. Level with the intervertebral disc space T13/L1, a filling defect is seen in the contrast column, surrounding the dural tube at the same level. No abnormalities of the dural tube are appreciated along the thoracic and lumbar spine.

**AGE**

2 Years

**COMPUTED TOMOGRAPHIC DIAGNOSIS**

- Suspect extradural myelocompression Th13/L1, accentuated from the right aspect

**INTERPRETED BY**

Sebastian Schaub, DVM  
Dr. med. vet. DipECVDI

**INTERPRETATION OF THE FINDINGS & FURTHER RECOMMENDATIONS**

The CT study is suspicious for material in the epidural space level T13/L1 with potential myelocompression. Unfortunately, the contrast media is distributing along the epidural space, resulting in an overall irregular contrast column and the appreciated material might be artefactual. If there is strong clinical suspicion for extradural myelocompression, repeating the myelographic study is recommended – consider a more cranial injection site level L5/L6.

**HOSPITAL NAME**

Catskill Veterinary  
Services, PLLC

**REFERRING VET**

Dr. Jessica Arrigan

**INVOICE**

59398

**DATE**

7-17-23



**PATIENT**

Helen Coccodrilli

**SPECIES**

Canine

**BREED**

Irish Setter

**SEX**

FS

**AGE**

2 Years

**INTERPRETED BY**

Sebastian Schaub, DVM  
Dr. med. vet. DipECVDI

**HOSPITAL NAME**

Catskill Veterinary  
Services, PLLC

**REFERRING VET**

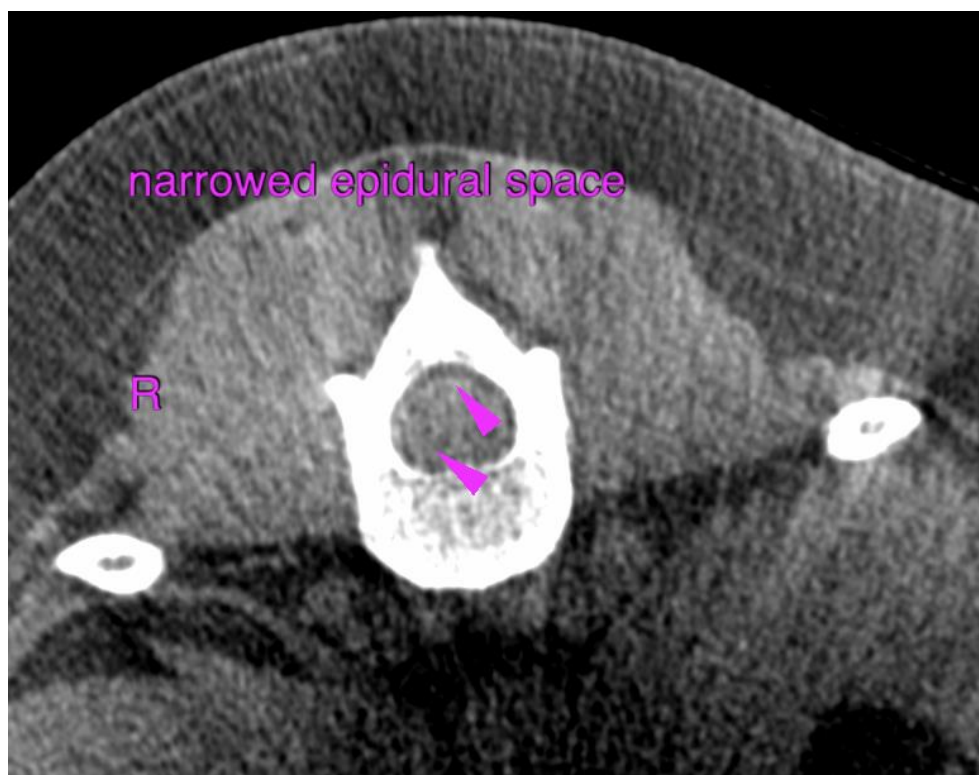
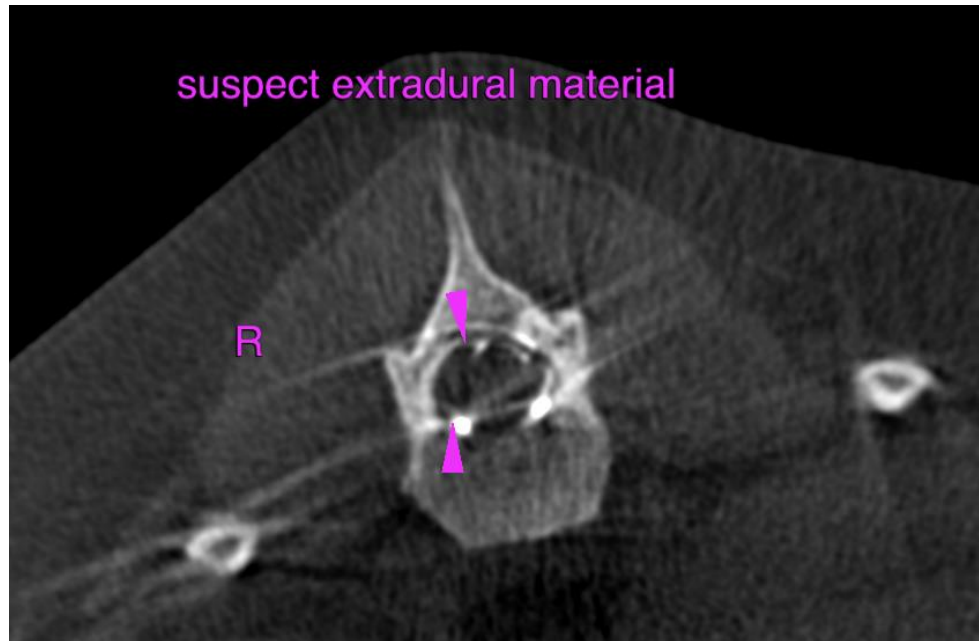
Dr. Jessica Arrigan

**INVOICE**

59398

**DATE**

7-17-23





**PATIENT**

Helen Coccodrilli

The information and recommendations provided are based on the images presented by the referring veterinarian/sonographer. No evaluation can be communicated regarding pathology that was not visible in the image/video clips provided.

**SPECIES**

Canine

Thank you for this referral. If the clinical or image interpretation does not parallel your findings or if I can be of any further assistance please contact me.

**BREED**

Irish Setter

**Sebastian Schaub**, Sebastian Schaub, DVM, Dr. med. vet. DipECVDI  
[info@sonopath.com](mailto:info@sonopath.com)

**SEX**

FS

**AGE**

2 Years

**INTERPRETED BY**

Sebastian Schaub, DVM  
Dr. med. vet. DipECVDI

**HOSPITAL NAME**

Catskill Veterinary  
Services, PLLC

**REFERRING VET**

Dr. Jessica Arrigan

**INVOICE**

59398

**DATE**

7-17-23