



PATIENT

Spicy Chopan

PRESENTING CLINICAL SIGNS

Nor eating drinking , no coughing in the last week ,coughing once a week may cause episodes of coughing no wheezes or crackles , was hard to listen to the heart on auscultation Abdominal breathing Has a history Of coughing & sneezing when she was recently adopted 3 months ago .

SPECIES

Feline

RADIOGRAPHIC STUDY OF THE THORAX

Radiographs of the thorax in three imaging planes are provided for review.

BREED

Domestic Medium Hair

RADIOGRAPHIC FINDINGS

The VD projection of the thorax is moderately rotated.

The surrounding bony structures are within normal limits.

The extrathoracic soft tissues present homogeneous without abnormalities.

SEX

Neutered Male

The cardiac silhouette is mildly elongated. The pulmonary vasculature is within normal limits.

The trachea is normal in diameter and presents the anticipated course. The luminal outline of the trachea is smooth.

AGE

19 Months

The bronchial tree presents with thin walls and tapers uniformly towards the periphery as expected.

The lung parenchyma presents the expected architecture and opacity; the intrapulmonary vascular branching is seen up to the third order lung vessels.

INTERPRETED BY

Sebastian Schaub, DVM
Dr. med. vet. DipECVDI

The diaphragm is well delineated with even surface and the expected mild cranial bulging of the diaphragmatic cupola.

RADIOGRAPHIC DIAGNOSIS

- Mild prominent cardiac silhouette

HOSPITAL NAME

Wilson Road Vet Clinic

INTERPRETATION OF THE FINDINGS & FURTHER RECOMMENDATIONS

The radiographic study of the thorax presents without abnormalities explaining the history of cough. Rule out upper respiratory tract infection as source for the presenting clinical signs. If clinical signs deteriorate, follow up radiographs of the thorax are recommended.

REFERRING VET

Dr, Nancy Abdelmalak

The mild elongation of the cardiac silhouette is very likely a normal anatomical variant. If clinically a cardiac murmur is appreciated or there is strong clinical suspicion for cardiomyopathy, a cardiac echo would be beneficial as advanced imaging modality.

INVOICE

52901

TECHNICAL COMMENTS

Gloved hands are seen in the primary beam, please consider radiation safety guidelines!

DATE

7-16-22



PATIENT

Spicy Chopan

SPECIES

Feline

BREED

Domestic Medium
Hair

SEX

Neutered Male

AGE

19 Months

INTERPRETED BY

Sebastian Schaub, DVM
Dr. med. vet. DipECVDI

HOSPITAL NAME

Wilson Road Vet
Clinic

REFERRING VET

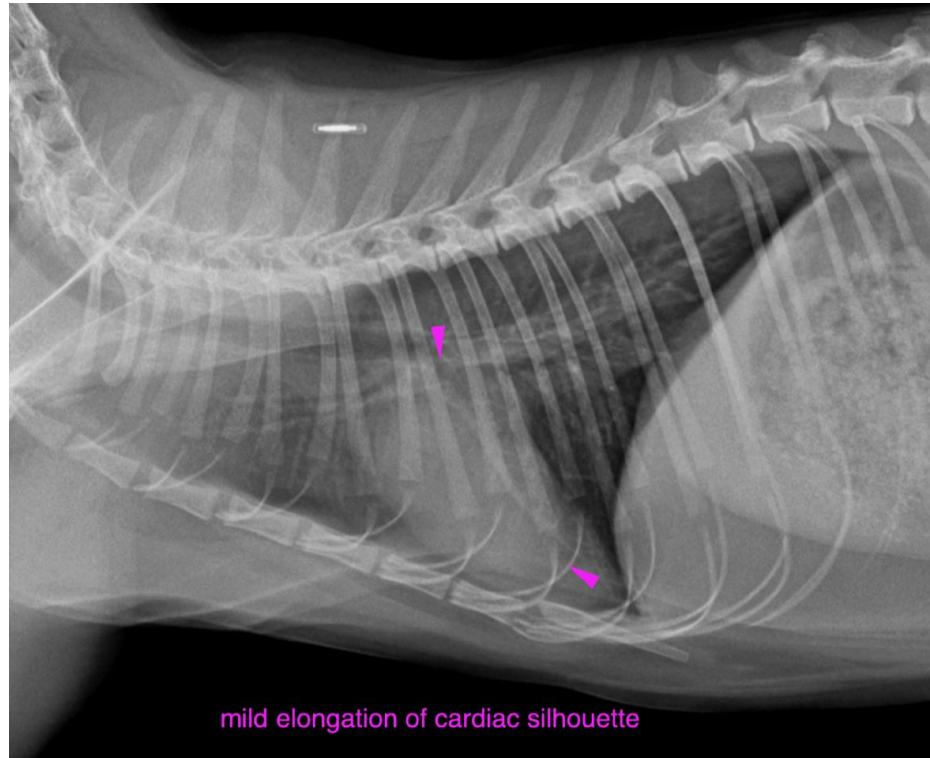
Dr, Nancy Abdelmalak

INVOICE

52901

DATE

7-16-22



The information and recommendations provided are based on the images presented by the referring veterinarian/sonographer. No evaluation can be communicated regarding pathology that was not visible in the image/video clips provided.

Thank you for this referral. If the clinical or image interpretation does not parallel your findings or if I can be of any further assistance please contact me.

Sebastian Schaub, Sebastian Schaub, DVM, Dr. med. vet. DipECVDI
sebast.schaub@gmail.com