



PATIENT

Sassy Williams

PRESENTING CLINICAL SIGNS

Elevated bile acids- suspect shunt Pre-surgically also scanned brain to rule out COM

SPECIES

Canine

COMPUTED TOMOGRAPHY OF THE ABDOMEN

A high resolution pre- and post-contrast CT study of the abdomen is provided for review.

BREED

Yorkshire Terrier

COMPUTED TOMOGRAPHIC FINDINGS

The serosal fat presents normal attenuation behavior. There is no evidence of peritoneal effusion or peritonitis.

SEX

F

Both kidneys present within normal limits for size, shape and organ architecture. After contrast administration a bilaterally symmetric and uniform nephro- and pyelogram is noted.

The adrenal glands are within normal limits for size, shape and organ architecture.

Both liver and spleen present with normal shape, even surface, uniformly attenuating parenchyma and homogeneous contrast enhancement, unremarkable.

AGE

1 Year

The portal vein presents a normal order of its tributary veins and intrahepatic branching. No abnormal vessel is noted inside and outside of the liver parenchyma.

INTERPRETED BY

Sebastian Schaub, DVM
Dr. med. vet. DipECVDI

The pancreas is evenly contoured, the pancreatic parenchyma is homogeneous and presents uniform contrast enhancement.

The position, delineation, wall and content of the gastrointestinal tract are considered within normal limits throughout.

HOSPITAL NAME

Southern Oregon
Veterinary Specialty
Center

The bony and surrounding soft tissue structures reveal no abnormalities.

COMPUTED TOMOGRAPHIC DIAGNOSIS

- No evidence of portosystemic shunting, neither intra- nor extrahepatic

REFERRING VET

Ravi Seshadri

INTERPRETATION OF THE FINDINGS & FURTHER RECOMMENDATIONS

No macroscopic vascular bypass of the liver was noted in the pre- and post- contrast studies of the abdomen. However, if the clinical signs are consistent with insufficiency of the liver primary non-cirrhotic portal hypertension (microvascular dysplasia) or other diffuse parenchymal liver disease would still be a potential and should be ruled out by means of ultrasound guided or surgical liver biopsy.

INVOICE

52906

DATE

7-16-22



PATIENT

Sassy Williams

SPECIES

Canine

BREED

Yorkshire Terrier

SEX

F

AGE

1 Year

INTERPRETED BY

Sebastian Schaub, DVM
Dr. med. vet. DipECVDI

HOSPITAL NAME

Southern Oregon
Veterinary Specialty
Center

REFERRING VET

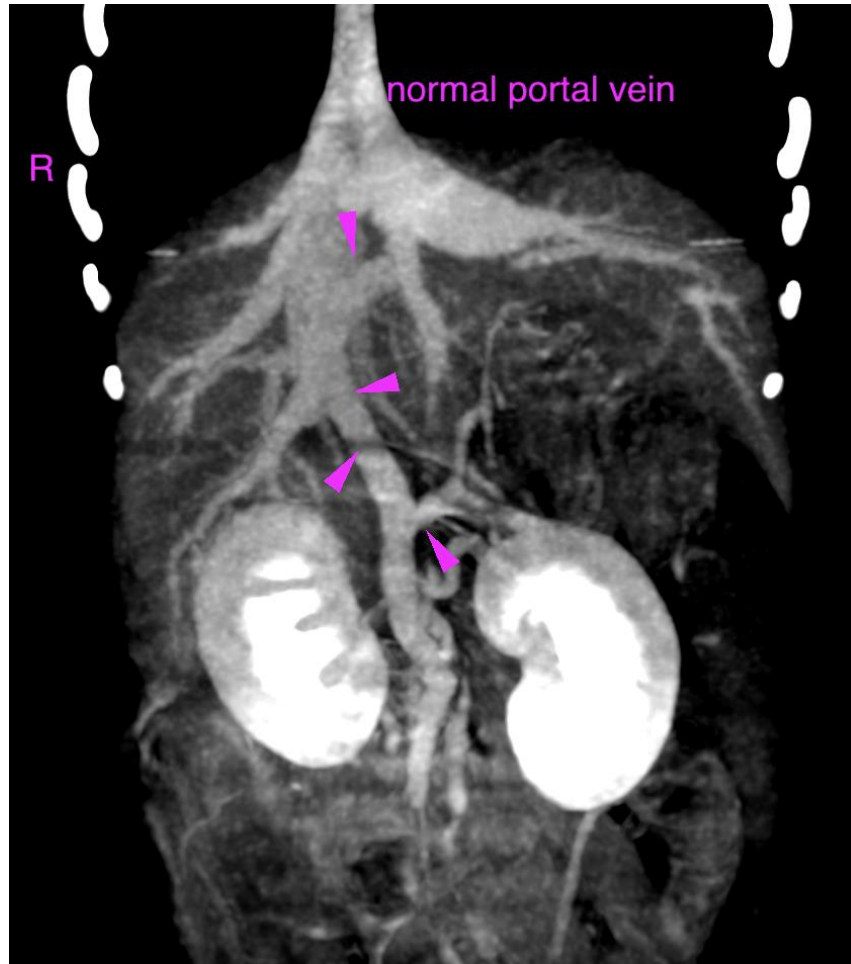
Ravi Seshadri

INVOICE

52906

DATE

7-16-22



The information and recommendations provided are based on the images presented by the referring veterinarian/sonographer. No evaluation can be communicated regarding pathology that was not visible in the image/video clips provided.

Thank you for this referral. If the clinical or image interpretation does not parallel your findings or if I can be of any further assistance please contact me.

Sebastian Schaub, Sebastian Schaub, DVM, Dr. med. vet. DipECVDI
sebast.schaub@gmail.com