



PATIENT

Cujo Smith

PRESENTING CLINICAL SIGNS

Ate pieces of tennis ball a week ago, is now constipated. Has vomited twice
Abnormal PE/Chem/CBC/UA Results: Owner Declined BW

SPECIES

Canine

RADIOGRAPHIC STUDY OF THE ABDOMEN

Radiographs of the abdomen in three imaging planes are provided for review.

BREED

American Bulldog Mix

RADIOGRAPHIC FINDINGS

The surrounding bony structures are within normal limits.

No abnormalities of the extraabdominal soft tissues are noted. The abdominal wall is smooth and thin.

The serosal detail is maintained throughout the peritoneal and retroperitoneal space.

SEX

Male

The liver is appropriate in position, size and presents uniform opacity.

The splenic head is in the anticipated position and within normal limits for size and opacity. The splenic body and tail are considered normal for position, size, shape and opacity.

AGE

2 Years

Both kidneys are seen and present with normal size, shape, delineation and opacity. The urinary bladder is in its anticipated position. No radiopaque calculi are noted throughout the upper and lower urinary tract.

INTERPRETED BY

Sebastian Schaub, DVM
Dr. med. vet. DipECVDI

The stomach is in its anticipated position and contains a small amount of gas and granular mineralized material.

The small intestinal loops are of even diameter and non-dilated, a small amount of gas is seen within the small intestinal loops and considered within normal limits.

HOSPITAL NAME

St. Catherine's Animal
Hospital

The colon is seen in the expected position and presents with appropriate content.

RADIOGRAPHIC DIAGNOSIS

- Empty stomach, but small amount of granular mineralized material

REFERRING VET

Dr. Jui Gokhale

INTERPRETATION OF THE FINDINGS & FURTHER RECOMMENDATIONS

The radiographic study of the abdomen presents without signs of gastrointestinal mechanical obstruction or evidence of clinically relevant gastric foreign material – but the small amount of mineralized material that appears unlikely to be related with clinical signs.

INVOICE

52905

DATE

7-16-22



PATIENT

Cujo Smith

SPECIES

Canine

BREED

American Bulldog Mix

SEX

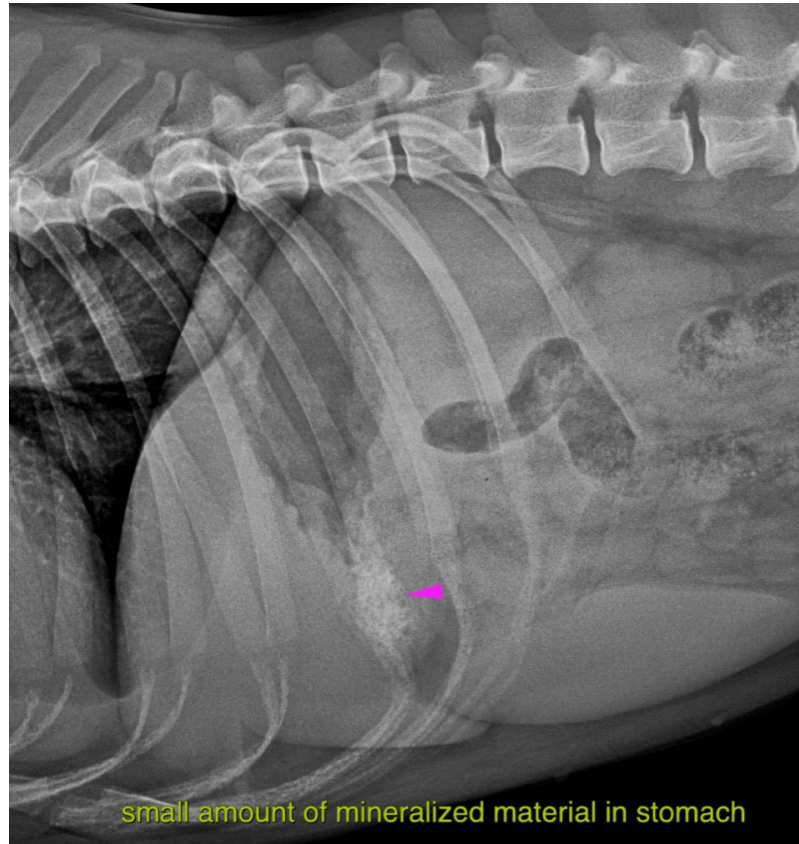
Male

AGE

2 Years

INTERPRETED BY

Sebastian Schaub, DVM
Dr. med. vet. DipECVDI



HOSPITAL NAME

St. Catherine's Animal
Hospital

REFERRING VET

Dr. Jui Gokhale

INVOICE

52905

DATE

7-16-22

The information and recommendations provided are based on the images presented by the referring veterinarian/sonographer. No evaluation can be communicated regarding pathology that was not visible in the image/video clips provided.

Thank you for this referral. If the clinical or image interpretation does not parallel your findings or if I can be of any further assistance please contact me.

Sebastian Schaub, Sebastian Schaub, DVM, Dr. med. vet. DipECVDI
sebast.schaub@gmail.com