



**PATIENT PRESENTING CLINICAL SIGNS**

Lulu Montull History: Panting for the last 3-4 weeks, xrays of the abdomen concerning for hepatomegaly vs abdominal mass or other.

**SPECIES** Abnormal PE/Chem/CBC/UA Results: ALT 205, GGT 13

Canine **COMPUTED TOMOGRAPHIC STUDY OF THE ABDOMEN**

A high resolution pre- and post-contrast CT study of the abdomen is provided for review.

**BREED** **COMPUTED TOMOGRAPHIC FINDINGS**

Mixed In the right caudoventral abdomen, attached to the ventral abdominal wall, a well-defined heterogeneous contrast enhancing soft tissue nodule, measuring 1.6 cm in size.

**SEX** Both kidneys present within normal limits for size, shape and organ architecture. After contrast administration multiple well-defined parenchymal filling defects are seen throughout the renal cortex. The cranial pole of the right adrenal gland presents with an intraparenchymal, post tcontrast mild hypoattenuating nodular lesion, measuring 8.8 mm in diameter. The left adrenal gland is generalized moderately enlarged, measuring up to 12 mm in diameter.

Spayed Female

**AGE**

14 Years The spleen presents with normal shape, even surface, uniformly attenuating parenchyma and homogeneous contrast enhancement, unremarkable.

**INTERPRETED BY** The hepatic volume is moderately increased the liver is protruding beyond the costal arch; the gastric axis is deviated caudally. The caudoventral hepatic margins are rounded. The hepatic parenchyma is uniform soft tissue attenuating and contrast enhancing.

Sebastian Schaub, DVM  
Dr. med. vet. DipECVDI

**HOSPITAL NAME** The pancreas is evenly contoured, the pancreatic parenchyma is homogeneous and presents uniform contrast enhancement.

Mobile Pet Imaging

The position, delineation, wall and content of the gastrointestinal tract are considered within normal limits throughout.

**REFERRING VET** The vertebral endplates L2/L3 present mild spondylosis formation.

Dr. Meaux

Both coxofemoral joints present moderate to marked osteophyte new bone formation. The acetabular groove bilaterally is shallow and the center of the femoral heads is lateral to the dorsal acetabular rim.

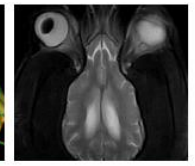
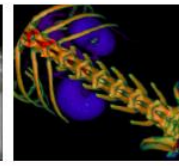
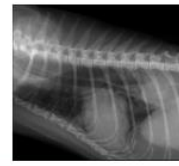
**INVOICE** In the subcutaneous tissue dorsal to L5/L6, two well-defined ovoid shaped nodules are visible.

16661

**COMPUTED TOMOGRAPHIC DIAGNOSIS**

- Hepatomegaly

7/15/22



**PATIENT**

Lulu Montull

- Right adrenal nodule and bilateral adrenomegaly
- Solitary peritoneal nodule right caudoventral abdomen
- Renal cortical cysts
- Advanced degenerative osteoarthritis coxofemoral joints bilaterally due to hip dysplasia
- Non-specific subcutaneous nodules dorsal to lumbar spine

**SPECIES**

Canine

**INTERPRETATION OF THE FINDINGS & FURTHER RECOMMENDATIONS**

**BREED**

Mixed

**SEX**

Spayed Female

Potentials for the hepatomegaly include metabolic hepatic disease, hepatitis or diffuse neoplastic infiltration. In case of doubt, ultrasound guided FNA sampling and/or Tru-cut biopsy can be used as minimally invasive methods for further workup.

The odds for (non)functional adrenal hyperplasia/macronodular hyperplasia are high. A potential for the intraparenchymal nodule of the right adrenal gland is neoplastic disease (e.g. adenoma, adenocarcinoma, pheochromocytoma). Testing of the pituitary adrenal axis is beneficial.

The peritoneal nodular in the right caudoventral abdomen is most suggestive for granuloma, aberrant lymphoid tissue or fat necrosis. Neoplasia (e.g. carcinoma, adenoma) is a consideration as well, but the odds appear low.

**AGE**

14 Years

**INTERPRETED BY**

Sebastian Schaub, DVM  
Dr. med. vet. DipECVDI

**HOSPITAL NAME**

Mobile Pet Imaging

**REFERRING VET**

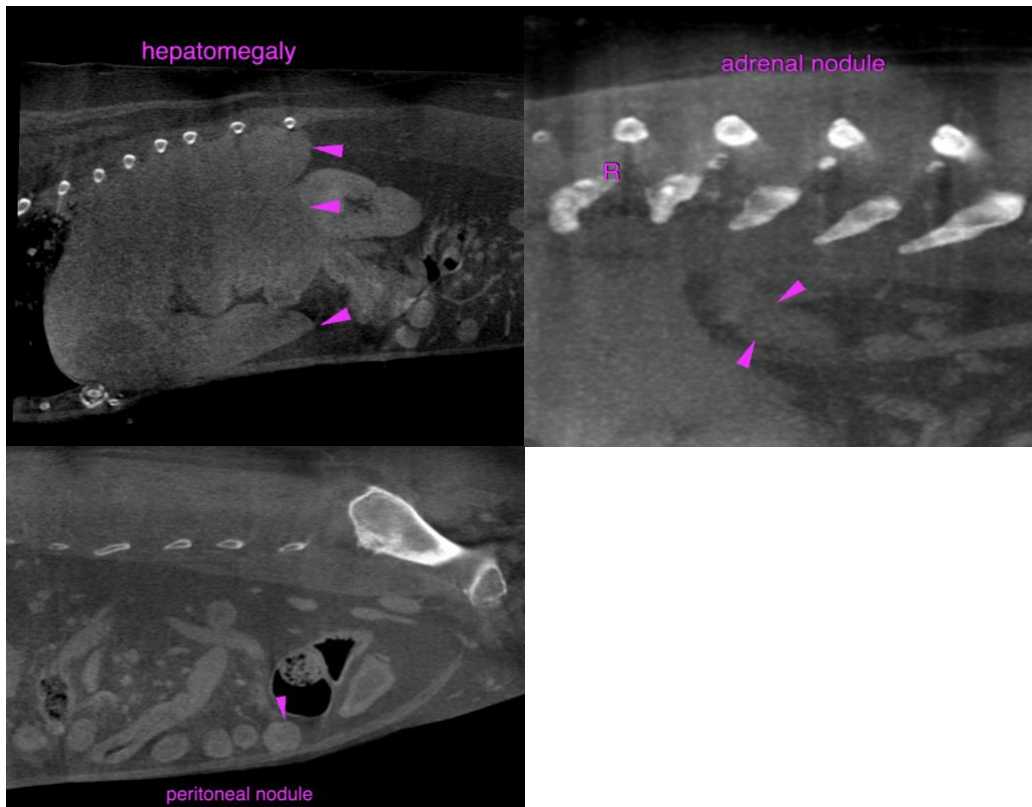
Dr. Meaux

**INVOICE**

16661

**DATE**

7/15/22





**PATIENT**

Lulu Montull

The information and recommendations provided are based on the images presented by the referring veterinarian/sonographer. No evaluation can be communicated regarding pathology that was not visible in the image/video clips provided.

**SPECIES**

Canine

Thank you for this referral. If the clinical or image interpretation does not parallel your findings or if I can be of any further assistance please contact me.

**Sebastian Schaub**, Sebastian Schaub, DVM, Dr. med. vet. DipECVDI  
sebast.schaub@gmail.com

**BREED**

Mixed

**SEX**

Spayed Female

**AGE**

14 Years

**INTERPRETED BY**

Sebastian Schaub, DVM  
Dr. med. vet. DipECVDI

**HOSPITAL NAME**

Mobile Pet Imaging

**REFERRING VET**

Dr. Meaux

**INVOICE**

16661

**DATE**

7/15/22