



PATIENT

Violet Stamenkovic

PRESENTING CLINICAL SIGNS

History of being unwell, high temperatures, vomiting, antibiotic therapy helps then symptoms come back, also coughing with purulent nasal discharge.

SPECIES

Canine

COMPUTED TOMOGRAPHY OF THE SKULL & THORAX

A pre- and post-contrast CT study of the skull and the thorax in a bone, lung and soft tissue reconstruction are provided for review.

BREED

Greyhound

COMPUTED TOMOGRAPHIC FINDINGS

Skull

The pictured parts of the dentition are complete and unremarkable in all jaw quadrants.

The nasal cavity presents the expected aerated spaces between thin & even conchae and turbinates with smooth mucosal lining.

SEX

Female

Both temporomandibular joints present congruent joint spaces with even subchondral bone surfaces and are considered within normal limits.

AGE

2 Years

The right tympanic bulla contains a small amount of soft tissue attenuating material. The left tympanic bulla is aerated, the mucosal lining is not seen, the bony wall is smooth and thin. The external ear canals are within normal limits.

INTERPRETED BY

Sebastian Schaub, DVM
Dr. med. vet. DipECVDI

The brain presents no deviation from normal anatomy and symmetry. The brain parenchyma is homogeneous and within normal limits for attenuation and distribution of contrast enhancement. The ventricular system is non-dilated and symmetric.

The submandibular and medial retropharyngeal lymph nodes are small and elongated with a normal short-to-long-axis-ratio is < 0.5, the attenuation and contrast enhancement pattern is uniform.

HOSPITAL NAME

Adelaide Plains
Veterinary Surgery

Thorax

The bony and surrounding soft tissue structures are within normal limits.

The sternal, cranial mediastinal and tracheobronchial lymph nodes are small elongated with a normal short-to-long-axis-ratio is < 0.5, the attenuation and contrast enhancement pattern is uniform and considered within normal limits.

REFERRING VET

John Katakasi

The cardiovascular structures including the pulmonary vasculature are within normal limits.

The bronchial tree presents with regular branching and tapers uniformly towards the periphery as expected, the bronchial walls are thin and smooth. The bronchus-to-artery ratio is within normal limits.

INVOICE

52868

The lung parenchyma presents the expected architecture and attenuation behavior, but small regions of dystelectasis of the dorsal dependent aspects of the lung parenchyma.

DATE

7-14-22

Small incidental gas pockets are seen within the esophageal lumen, there is no evidence of abnormal dilation.



PATIENT

Violet Stamenkovic

COMPUTED TOMOGRAPHIC DIAGNOSIS

- Mild right sided otitis media
- Structural normal thorax, but mild dystelectasis of the dorsal dependent aspects of the lung parenchyma

SPECIES

Canine

INTERPRETATION OF THE FINDINGS & FURTHER RECOMMENDATIONS

The CT study of the skull and thorax presents without clinically relevant macromorphological abnormalities; at this point there is no evidence of active rhinitis or pneumonia.

BREED

Greyhound

The right sided mild otitis media might be a sequela to preceding upper respiratory tract disease.

SEX

Female

AGE

2 Years

INTERPRETED BY

Sebastian Schaub, DVM
Dr. med. vet. DipECVDI

HOSPITAL NAME

Adelaide Plains
Veterinary Surgery

REFERRING VET

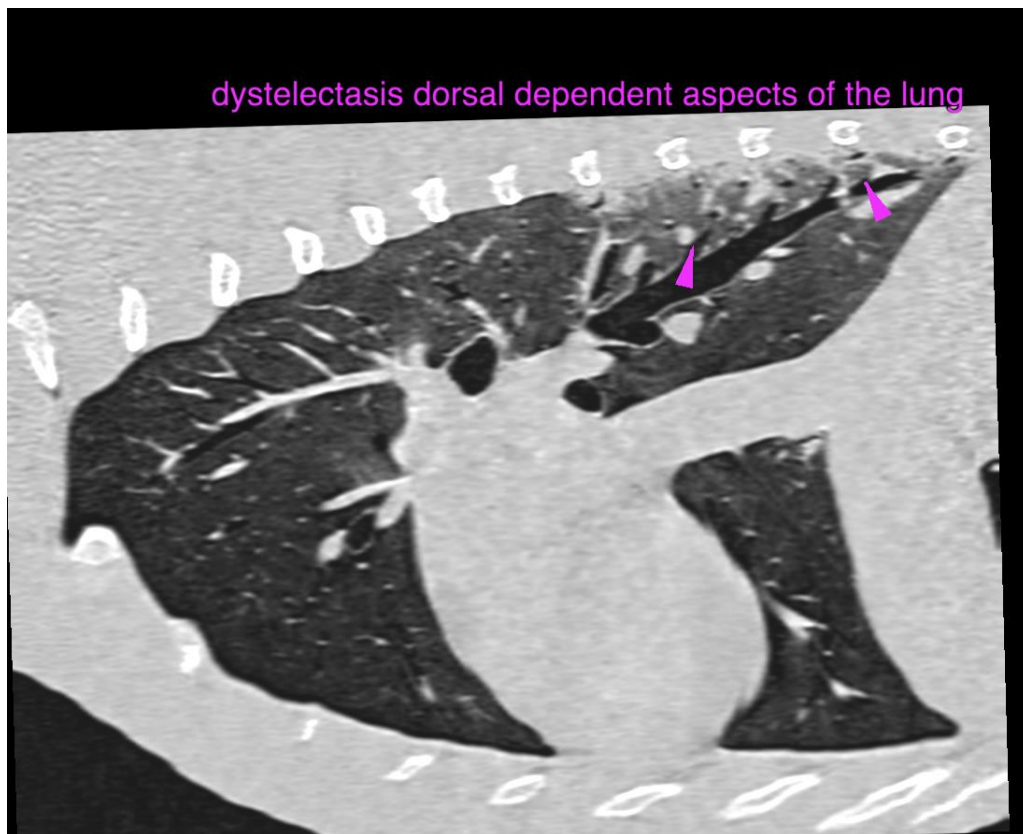
John Katakasi

INVOICE

52868

DATE

7-14-22





PATIENT

Violet Stamenkovic

SPECIES

Canine

BREED

Greyhound

SEX

Female

AGE

2 Years

INTERPRETED BY

Sebastian Schaub, DVM
Dr. med. vet. DipECVDI

HOSPITAL NAME

Adelaide Plains
Veterinary Surgery

REFERRING VET

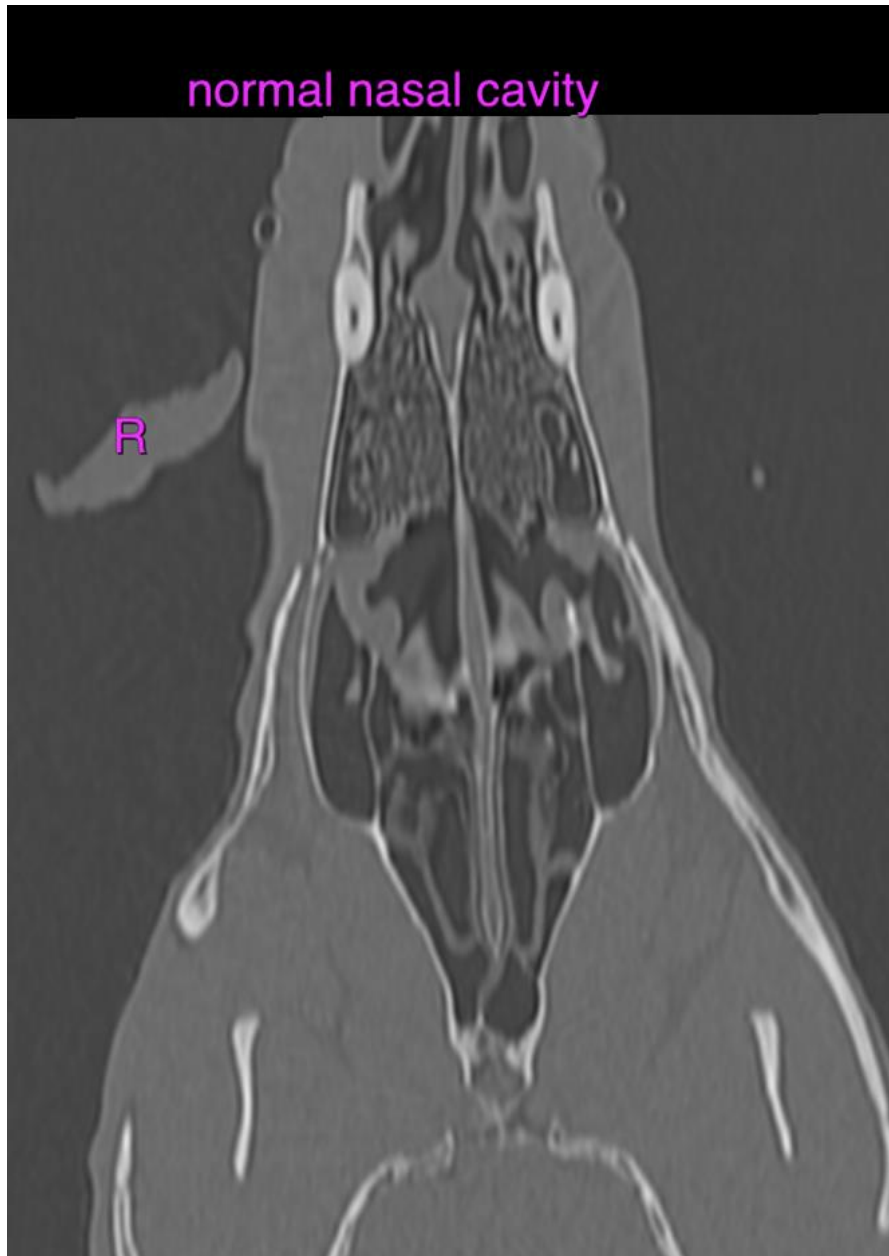
John Katakasi

INVOICE

52868

DATE

7-14-22





PATIENT

Violet Stamenkovic

SPECIES

Canine

BREED

Greyhound

SEX

Female

AGE

2 Years

INTERPRETED BY

Sebastian Schaub, DVM
Dr. med. vet. DipECVDI

HOSPITAL NAME

Adelaide Plains
Veterinary Surgery

REFERRING VET

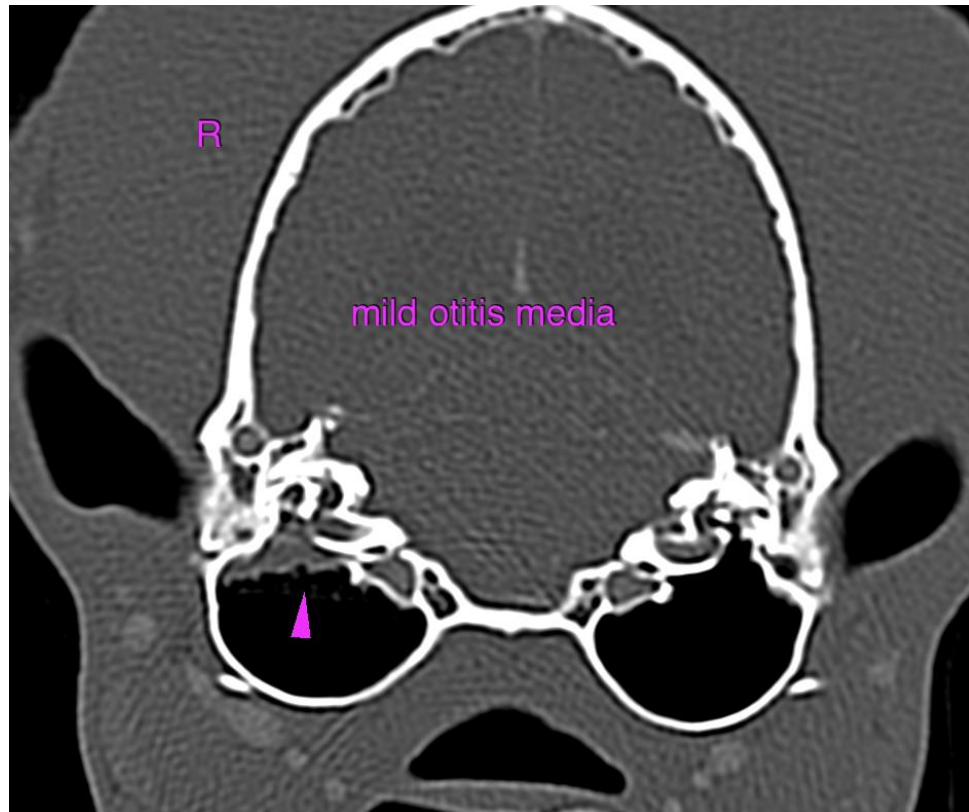
John Katakasi

INVOICE

52868

DATE

7-14-22



The information and recommendations provided are based on the images presented by the referring veterinarian/sonographer. No evaluation can be communicated regarding pathology that was not visible in the image/video clips provided.

Thank you for this referral. If the clinical or image interpretation does not parallel your findings or if I can be of any further assistance please contact me.

Sebastian Schaub, Sebastian Schaub, DVM, Dr. med. vet. DipECVDI
sebast.schaub@gmail.com