

**PATIENT**

Teddy O'Malley

PRESENTING CLINICAL SIGNS

Non-Weight bearing Rt. Hindleg ; Drawer = 4 ; Suspect Cranial Cruciate Rupture +/- Meniscal Tear
Abnormal PE/Chem/CBC/UA Results: Current Meds: Carprofen CBC/CHEM: CBC WNL ;
Miniscreen = WNL Urinalysis = Not done

SPECIES

Canine

RADIOGRAPHIC STUDY OF THE PELVIS AND STIFLE JOINTS

Radiographs of the pelvis in a VD view and the stifle joints in two orthogonal imaging planes are provided for review.

BREED

Pomeranian Mix

RADIOGRAPHIC FINDINGS

The osseous and surrounding soft tissue structures of the pelvis are within normal limits. Both coxofemoral joints present smooth osseous margins and congruent joint spaces.

SEX

MN

The volume of the soft tissue shadow of the right thigh musculature is mild to moderately decreased.

The left stifle joint presents smooth osseous margins and without evidence of intracapsular swelling, unremarkable.

AGE

6 Years

At the proximal aspect of the trochlear ridge of the right femur, very mild osteophyte formation is appreciated. The right stifle joint presents a mild to moderate intracapsular swelling, partially effacing the infrapatellar fat pad and distorting the fascial plane caudally.

INTERPRETED BY

Sebastian Schaub, DVM
Dr. med. vet. DipECVDI

RADIOGRAPHIC DIAGNOSIS

- Very mild degenerative osteoarthritis right stifle joint
- Moderate articular swelling right stifle joint
- Disuse atrophy right thigh musculature
- Normal pelvis & coxofemoral joints
- Normal left stifle joint

HOSPITAL NAME

Byram Animal
Hospital

INTERPRETATION OF THE FINDINGS & FURTHER RECOMMENDATIONS**REFERRING VET**

Dr. Maria Cruz

The radiographic study is consistent with very mild degenerative osteoarthritis with concomitant joint effusion of the right stifle joint. The most-likely underlying cause is (partial) rupture of the cranial cruciate ligament with or without meniscal disease.

A positive drawer sign or tibial compression test (under general anesthesia) can be used to confirm the diagnosis.

INVOICE

52869

DATE

7-14-22



PATIENT

Teddy O'Malley

SPECIES

Canine

BREED

Pomeranian Mix

SEX

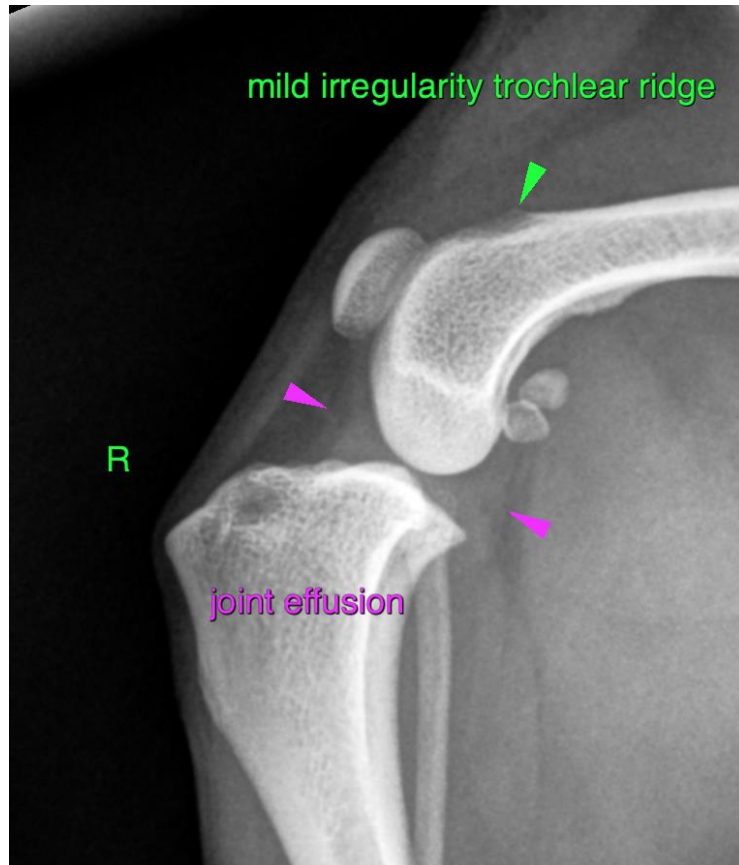
MN

AGE

6 Years

INTERPRETED BY

Sebastian Schaub, DVM
Dr. med. vet. DipECVDI



HOSPITAL NAME

Byram Animal
Hospital

REFERRING VET

Dr. Maria Cruz

INVOICE

52869

DATE

7-14-22

The information and recommendations provided are based on the images presented by the referring veterinarian/sonographer. No evaluation can be communicated regarding pathology that was not visible in the image/video clips provided.

Thank you for this referral. If the clinical or image interpretation does not parallel your findings or if I can be of any further assistance please contact me.

Sebastian Schaub, Sebastian Schaub, DVM, Dr. med. vet. DipECVDI
sebast.schaub@gmail.com