



PATIENT PRESENTING CLINICAL SIGNS

Twitch Brown Reason for Visit: URINARY History: pet is here for poss blocked/ owner states pet was blocked about 1 month ago. Owner states pet is showing same signs of previous blockage/ walking around house meowing/ owners other cat also noted and started smelling a drop of urine on the floor

SPECIES Abnormal PE/Chem/CBC/UA Results: Hydration: Appropriately hydrated Mentation: BAR EENT: No nasal discharge; clear no discharge OU; clean no debris AU; No cough on tracheal palpation. Oral Cavity: dental tartar present Lymph Nodes: Symmetrical, no changes in size, shape, consistency Skin: Good hair coat CV/Respiratory: No murmur or crackles/wheezing auscultated. Normal bronchovesicular sounds. Abd/GI: Soft non painful abdomen, no palpable organomegaly or abnormalities Uro/Perineum: N, small bladder Musculoskeletal: Ambulatory x4, no lameness noted. BCS 7/9 Neurological: tremors - cerebellar disease, otherwise WNL

BREED DSH **RADIOGRAPHIC STUDY OF THE ABDOMEN**

Radiographs of the abdomen in two imaging planes are provided for review.

SEX **RADIOGRAPHIC FINDINGS**

NM The surrounding bony structures are within normal limits.

AGE No abnormalities of the extraabdominal soft tissues are noted. The abdominal wall is smooth and thin.

The serosal detail is maintained throughout the peritoneal and retroperitoneal space.

12 Years, 1 Month The liver is appropriate in position, size and presents uniform opacity.

INTERPRETED BY The splenic head is in the anticipated position and within normal limits for size and opacity. The splenic body and tail are considered normal for position, size, shape and opacity.

Sebastian Schaub, DVM
Dr. med. vet. DipECVDI

Both kidneys are seen and present with normal size, shape, delineation and opacity. The urinary bladder is in its anticipated position. No radiopaque calculi are noted throughout the upper and lower urinary tract.

HOSPITAL NAME The stomach is in its anticipated position and presents normal content.

DPC Veterinary Hospital The small intestinal loops are of even diameter and non-dilated, a small amount of gas is seen within the small intestinal loops and considered within normal limits.

REFERRING VET The colon is seen in the expected position and presents with appropriate content.

RADIOGRAPHIC DIAGNOSIS

- Normal abdomen

INVOICE INTERPRETATION OF THE FINDINGS & FURTHER RECOMMENDATIONS

59364 The radiographic study of the abdomen presents without abnormalities.

DATE

7-13-23



PATIENT

Twitch Brown

SPECIES

Feline

BREED

DSH

SEX

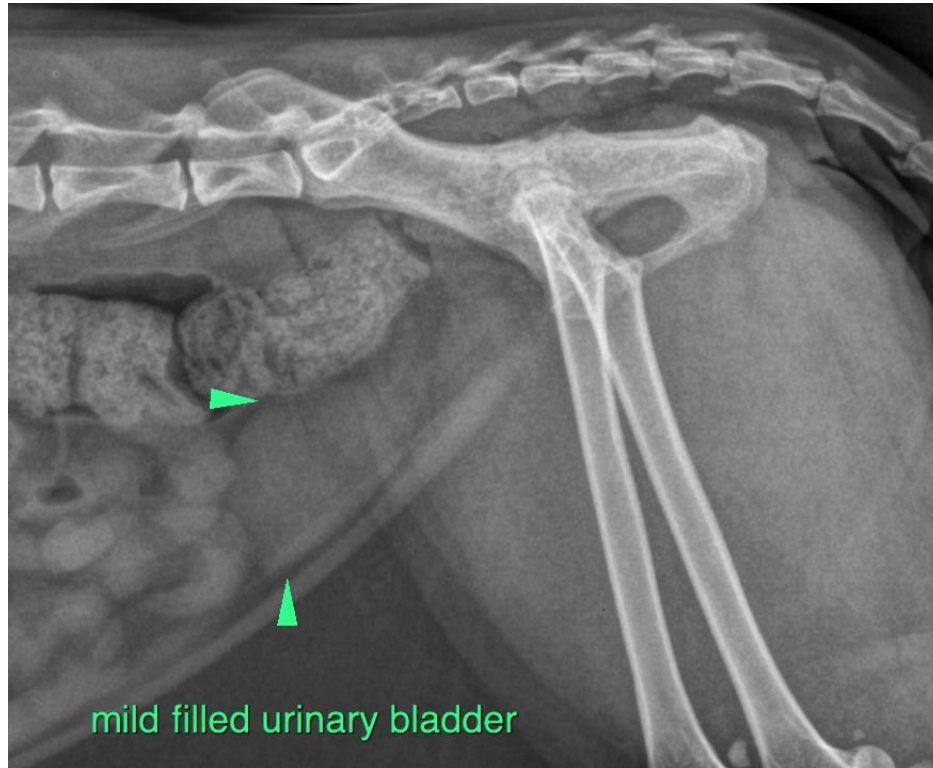
NM

AGE

12 Years, 1 Month

INTERPRETED BY

Sebastian Schaub, DVM
Dr. med. vet. DipECVDI



HOSPITAL NAME

DPC Veterinary
Hospital

The information and recommendations provided are based on the images presented by the referring veterinarian/sonographer. No evaluation can be communicated regarding pathology that was not visible in the image/video clips provided.

Thank you for this referral. If the clinical or image interpretation does not parallel your findings or if I can be of any further assistance please contact me.

REFERRING VET

Dr. White

Sebastian Schaub, Sebastian Schaub, DVM, Dr. med. vet. DipECVDI
info@sonopath.com

INVOICE

59364

DATE

7-13-23