



**PATIENT PRESENTING CLINICAL SIGNS**

Spitfire Livingston  
Dogs Kennel  
Came in 6/27 and was diagnosed with pneumonia. Went to ER for treatment. Just finished antibiotics yesterday and has been doing great.

**RADIOGRAPHIC STUDY OF THE THORAX**

**SPECIES** Radiographs of the thorax in three imaging planes are provided for review.

Canine **RADIOGRAPHIC FINDINGS**

The surrounding bony structures are within normal limits.

**BREED** The extrathoracic soft tissues present homogeneous without abnormalities.

Brittany  
The heart is of normal size and shape, there is no evidence of cardiac chamber or vascular enlargement. The pulmonary vasculature is within normal limits.

**SEX** The cranial mediastinum presents the expected soft tissue opacity. The mediastinal width is less than twice the width of the vertebral column at the same level.

Male  
The trachea is normal in diameter and presents the anticipated course. The luminal outline of the trachea is smooth.

**AGE** The bronchial tree presents with thin walls and tapers uniformly towards the periphery as expected.

3 Years  
The lung parenchyma presents the expected architecture and opacity – complete remission of the alveolar pattern is appreciated; the intrapulmonary vascular branching is seen up to the third order lung vessels.

**INTERPRETED BY**

Sebastian Schaub, DVM  
Dr. med. vet. DipECVDI

The diaphragm is well delineated with even surface and the expected mild cranial bulging of the diaphragmatic cupola.

**RADIOGRAPHIC DIAGNOSIS**

**HOSPITAL NAME**

- Remission of the alveolar pattern

Elizabeth Animal  
Hospital

**INTERPRETATION OF THE FINDINGS & FURTHER RECOMMENDATIONS**

In comparison to the previous radiographic study, there is complete remission of the pneumonic changes of the lung parenchyma.

**REFERRING VET**

Leon Anderson, DVM

**INVOICE**

59366

**DATE**

7-13-23



**PATIENT**

Spitfire Livingston  
Dogs Kennel

**SPECIES**

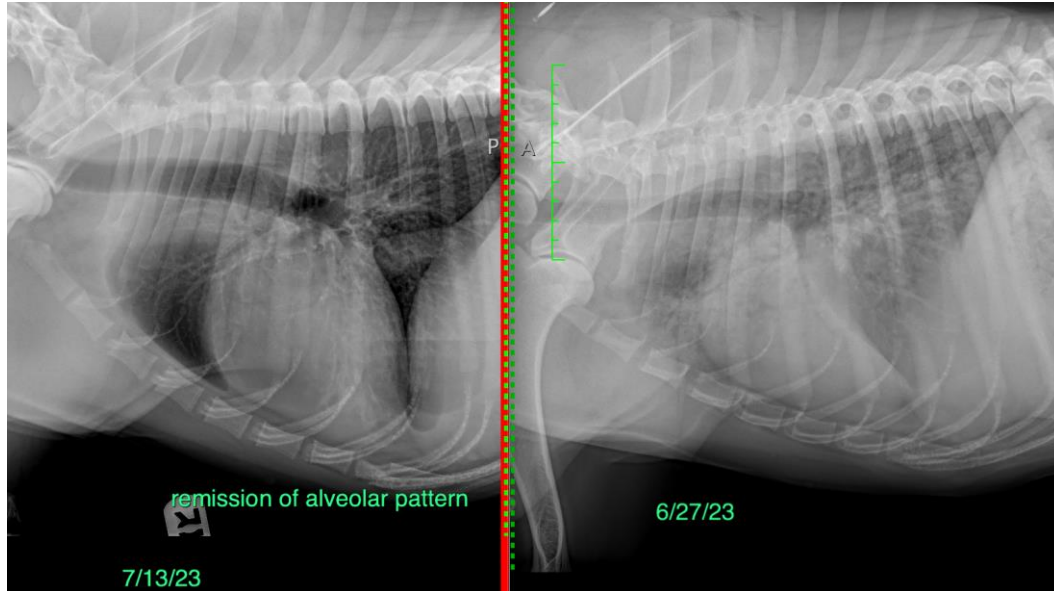
Canine

**BREED**

Brittany

**SEX**

Male



**AGE**

3 Years

**INTERPRETED BY**

Sebastian Schaub, DVM  
Dr. med. vet. DipECVDI

The information and recommendations provided are based on the images presented by the referring veterinarian/sonographer. No evaluation can be communicated regarding pathology that was not visible in the image/video clips provided.

Thank you for this referral. If the clinical or image interpretation does not parallel your findings or if I can be of any further assistance please contact me.

**HOSPITAL NAME**

Elizabeth Animal  
Hospital

**Sebastian Schaub**, Sebastian Schaub, DVM, Dr. med. vet. DipECVDI  
[info@sonopath.com](mailto:info@sonopath.com)

**REFERRING VET**

Leon Anderson, DVM

**INVOICE**

59366

**DATE**

7-13-23