



PATIENT PRESENTING CLINICAL SIGNS

Grady Reynolds Lameness right thoracic limb
Abnormal PE/Chem/CBC/UA Results: Moderate joint thickening on the right elbow

SPECIES COMPUTED TOMOGRAPHY OF THE RIGHT FRONT LIMB

Canine A high resolution plain CT study of the right front limb is provided for review.

COMPUTED TOMOGRAPHIC FINDINGS

BREED The osseous and surrounding soft tissue structures of the right shoulder joint are within normal limits.

Labrador Retriever The periarticular bones of the right elbow joint present moderate osteophyte new bone formation. The medial coronoid process of the right elbow joint has an irregular hook shaped conformation and heterogeneous density. The joint space of the medial compartment of the right elbow joint is narrowed.

SEX The included parts of the left elbow joint present osteophyte new bone formation and an irregular marginated medial coronoid process with a heterogeneous attenuation pattern.

MN

COMPUTED TOMOGRAPHIC DIAGNOSIS

- AGE**
- Coronoid disease elbow joints bilaterally
 - Narrowed medial compartment right elbow joint
 - Degenerative osteoarthritis elbow joints bilaterally, R>L
 - Structural normal right shoulder joint
- 8 Years

INTERPRETED BY

Sebastian Schaub, DVM
Dr. med. vet. DipECVDI

INTERPRETATION OF THE FINDINGS & FURTHER RECOMMENDATIONS

The degenerative joint disease of the right elbow joint due to underlying coronoid disease is a plausible cause for the right front limb lameness. The narrowed medial compartment of the right elbow joint is suggestive for advanced erosion of the joint cartilage. Arthroscopy/arthrotomy might be considered to revise the right elbow joint and adjuvant palliative treatment options for the advanced degenerative joint disease should be discussed with orthopedic surgeon as well.

HOSPITAL NAME

Animal Surgical
Center - Oceanside

REFERRING VET

North Shore
Veterinary Hospital

INVOICE

59358

DATE

7-13-23



PATIENT

Grady Reynolds

SPECIES

Canine

BREED

Labrador Retriever

SEX

MN

AGE

8 Years

INTERPRETED BY

Sebastian Schaub, DVM
Dr. med. vet. DipECVDI

HOSPITAL NAME

Animal Surgical
Center - Oceanside

REFERRING VET

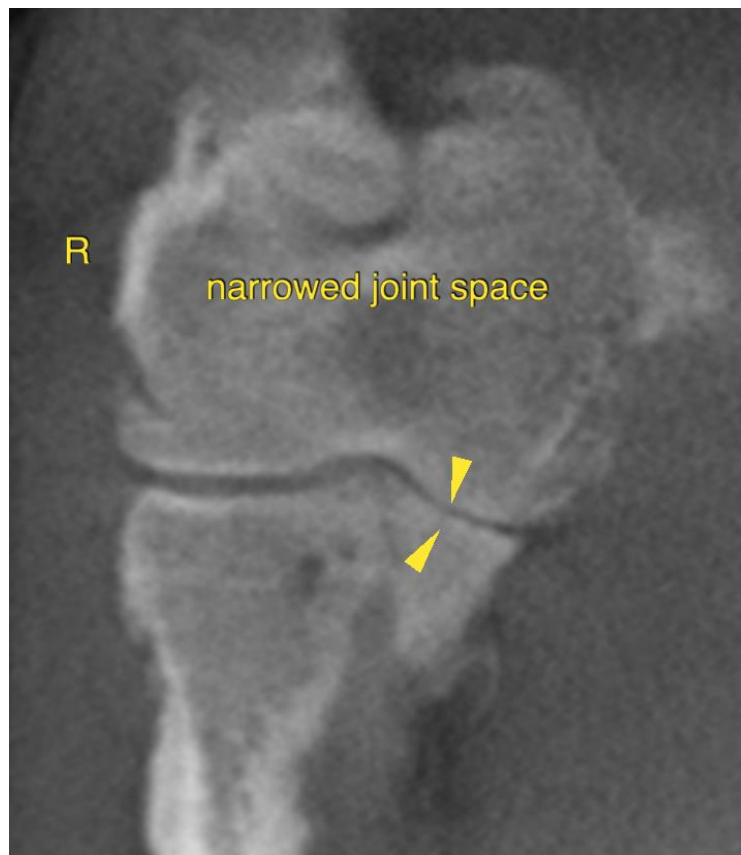
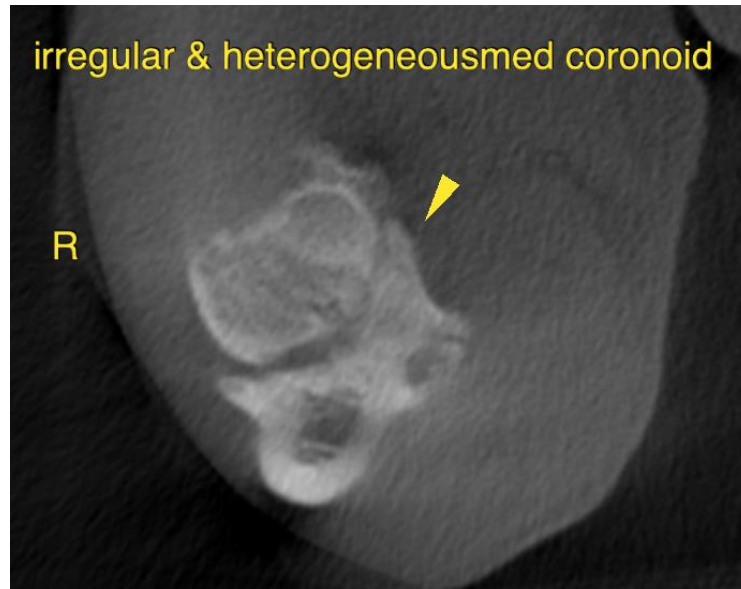
North Shore
Veterinary Hospital

INVOICE

59358

DATE

7-13-23





PATIENT

Grady Reynolds

The information and recommendations provided are based on the images presented by the referring veterinarian/sonographer. No evaluation can be communicated regarding pathology that was not visible in the image/video clips provided.

SPECIES

Canine

Thank you for this referral. If the clinical or image interpretation does not parallel your findings or if I can be of any further assistance please contact me.

BREED

Labrador Retriever

Sebastian Schaub, Sebastian Schaub, DVM, Dr. med. vet. DipECVDI
info@sonopath.com

SEX

MN

AGE

8 Years

INTERPRETED BY

Sebastian Schaub, DVM
Dr. med. vet. DipECVDI

HOSPITAL NAME

Animal Surgical
Center - Oceanside

REFERRING VET

North Shore
Veterinary Hospital

INVOICE

59358

DATE

7-13-23