



PATIENT PRESENTING CLINICAL SIGNS

Zoey Figueroa Progressively worsening lockjaw over past 2 months. Past 2 weeks pet cannot open mouth at all; completely closed shut. Unable to open mouth at all even under sedation with Propofol.

SPECIES COMPUTED TOMOGRAPHY OF THE SKULL

Canine A high resolution pre- and post-contrast CT study of the skull is provided for review.

COMPUTED TOMOGRAPHIC FINDINGS

BREED

The pictured parts of the dentition are complete and unremarkable in all jaw quadrants.

Golden Doodle

Advanced atrophy of the masticatory musculature is present. The temporal muscle bilaterally presents a mild irregular contrast enhancement pattern.

SEX

The nasal cavity presents the expected aerated spaces between thin & even conchae and turbinates with smooth mucosal lining.

FS

Both temporomandibular joints present congruent joint spaces with even subchondral bone surfaces and are considered within normal limits.

AGE

Both tympanic bullae contain a moderate amount of fluid attenuating material. The external ear canals are within normal limits.

2 Years, 2 Months

The brain presents no deviation from normal anatomy and symmetry. The brain parenchyma is homogeneous and within normal limits for attenuation and distribution of contrast enhancement. The ventricular system is non-dilated and symmetric.

INTERPRETED BY

The submandibular and medial retropharyngeal lymph nodes are prominent.

**Sebastian Schaub, DVM
Dr. med. vet. DipECVDI**

COMPUTED TOMOGRAPHIC DIAGNOSIS

- Generalized myopathy restricted to the masticatory muscles with advances atrophy and irregular contrast enhancement pattern.
- Lymphadenopathy mandibular and medial retropharyngeal lymph nodes bilaterally
- Bilateral otitis media

HOSPITAL NAME

**Mobile Pet Imaging
CFL**

INTERPRETATION OF THE FINDINGS & FURTHER RECOMMENDATIONS

REFERRING VET

Borecky

The findings are suggestive for chronic masticatory muscle myositis. Complementing workup by a type 2M fibers antibody assay, muscle biopsy of the temporalis muscle and an electromyography can help to confirm the diagnosis. Due to the lack of swelling or signs for overt inflammation, infectious myositis (e.g. Hepatozoon sp) is unlikely.

INVOICE

52859

For dogs with masticatory muscle myositis in a chronic phase, the long term prognosis is guarded. Secondary reactive hyperplasia of the tributary lymph nodes.

DATE

7-13-22



PATIENT

Zoey Figueroa

SPECIES

Canine

BREED

Golden Doodle

SEX

FS

AGE

2 Years, 2 Months

INTERPRETED BY

Sebastian Schaub, DVM
Dr. med. vet. DipECVDI

HOSPITAL NAME

Mobile Pet Imaging
CFL

REFERRING VET

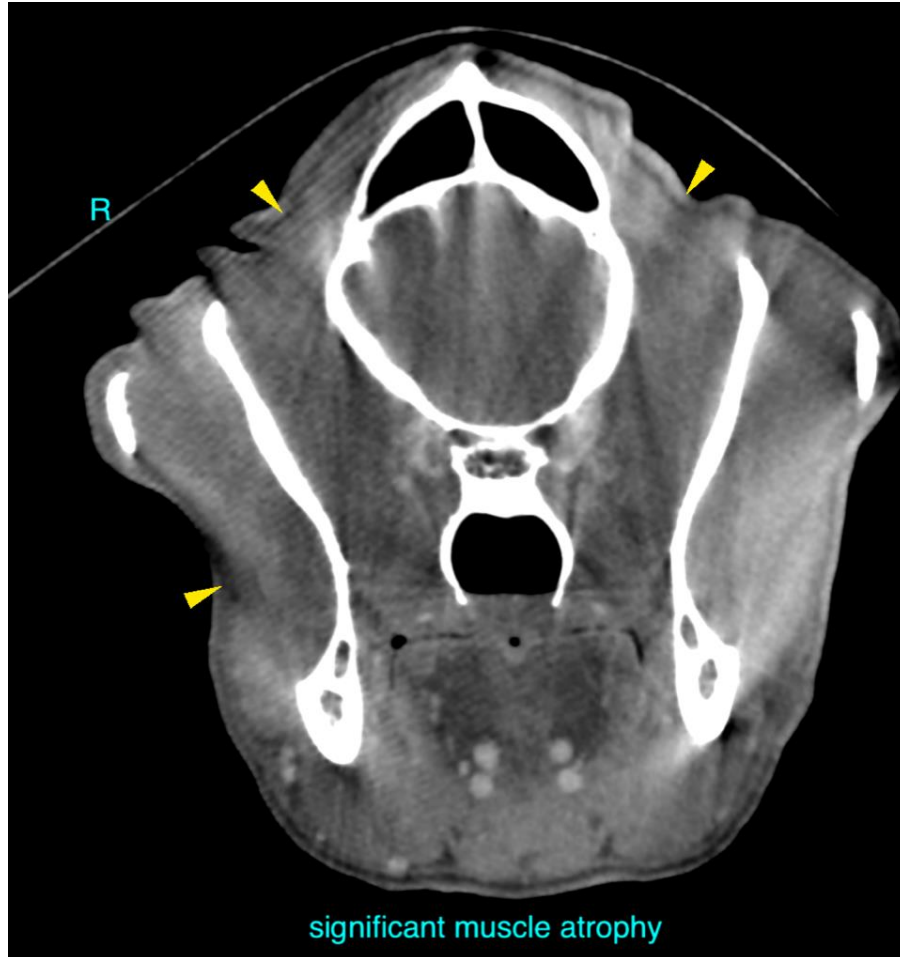
Borecky

INVOICE

52859

DATE

7-13-22



The information and recommendations provided are based on the images presented by the referring veterinarian/sonographer. No evaluation can be communicated regarding pathology that was not visible in the image/video clips provided.

Thank you for this referral. If the clinical or image interpretation does not parallel your findings or if I can be of any further assistance please contact me.

Sebastian Schaub, Sebastian Schaub, DVM, Dr. med. vet. DipECVDI
sebast.schaub@gmail.com