



PATIENT PRESENTING CLINICAL SIGNS

Maverick Daniels Weak in the rear legs, having a hard time getting around. Most notable right when he wakes up, or after exercise, but seems to have a "good period" in the middle of his walks. Defecating small amounts while sleeping. No change on carprofen and CBD

SPECIES Abnormal PE/Chem/CBC/UA Results: Stoic dog, no appreciable pain anywhere. CP WNL on rear legs. Decreased flexion throughout lumbar spine, possible slightly reduced extension of both hips.

Canine

RADIOGRAPHIC STUDY OF THE LUMBAR SPINE AND STIFLE JOINTS

Radiographs of the lumbar spine and the stifle joints in two orthogonal imaging planes are provided for review.

BREED

German Shepherd

RADIOGRAPHIC FINDINGS

SEX Multiple facet-joints along the lumbar spine present mild to moderate osteophyte new bone formation. The vertebral endplates L2/L3 and L7/S1 present mild lateral spondylosis formation – superimposing with the respective neuroforamina.

MN The periarticular bones of the left stifle joint are smooth and no evidence of an intracapsular soft tissue swelling is appreciated.

AGE The periarticular bones of the right stifle joint are smooth and a moderate intracapsular soft tissue swelling is noted, partially effacing the infrapatellar fat-pad.

8 Years

RADIOGRAPHIC DIAGNOSIS

INTERPRETED BY

Sebastian Schaub, DVM
Dr. med. vet. DipECVDI

- Articular swelling right stifle joint
- Multifocal spondylarthrosis
- Spondylosis deformans

HOSPITAL NAME

Northshore
Veterinary Hospital

INTERPRETATION OF THE FINDINGS & FURTHER RECOMMENDATIONS

The radiographic study of the lumbar spine reveals only mild degenerative changes. If there is strong suspicion for underlying myelopathy, consider complementing workup by cross-sectional imaging of the spine.

REFERRING VET

Kristin Williams

The effusion of the right stifle joint can be traumatic, degenerative or primary inflammatory in origin; a common cause for effusion of the stifle joint is pathology of the cranial cruciate ligament ± meniscal pathology.

INVOICE

59324

DATE

7-12-23



PATIENT

Maverick Daniels

SPECIES

Canine

BREED

German Shepherd

SEX

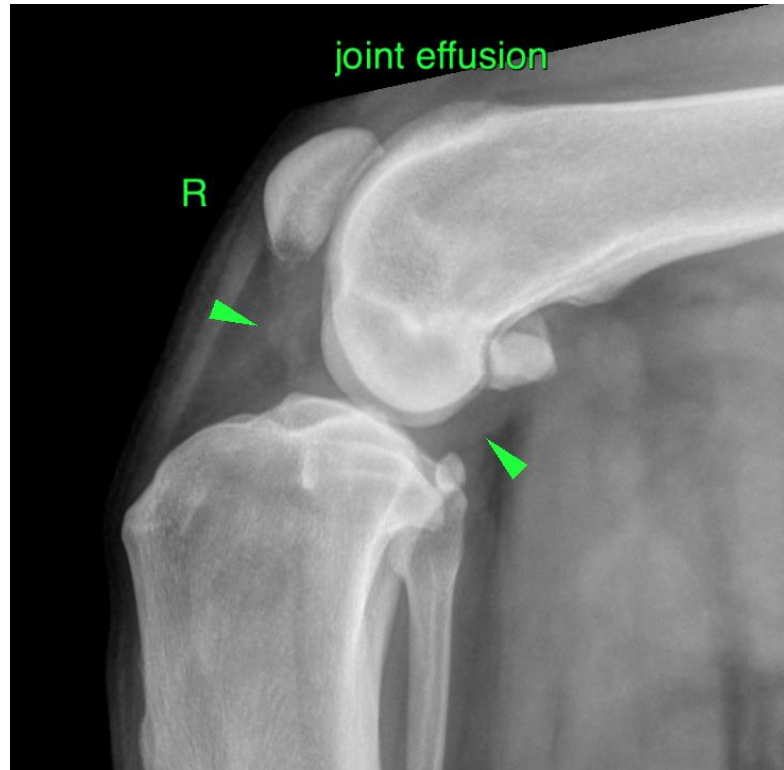
MN

AGE

8 Years

INTERPRETED BY

Sebastian Schaub, DVM
Dr. med. vet. DipECVDI



HOSPITAL NAME

Northshore
Veterinary Hospital

The information and recommendations provided are based on the images presented by the referring veterinarian/sonographer. No evaluation can be communicated regarding pathology that was not visible in the image/video clips provided.

Thank you for this referral. If the clinical or image interpretation does not parallel your findings or if I can be of any further assistance please contact me.

REFERRING VET

Kristin Williams

Sebastian Schaub, Sebastian Schaub, DVM, Dr. med. vet. DipECVDI
info@sonopath.com

INVOICE

59324

DATE

7-12-23