



PATIENT

Paws Sroga

PRESENTING CLINICAL SIGNS

Coughing x 6 months, eupneic, no murmur. Heartworm test pending, Evaluate lungs for asthma.

RADIOGRAPHIC STUDY OF THE THORAX

SPECIES

Feline

Radiographs of the thorax in three imaging planes are provided for review.

RADIOGRAPHIC FINDINGS

The surrounding bony structures are within normal limits.

BREED

DSH

The extrathoracic soft tissues present homogeneous without abnormalities.

The heart is of normal size and shape, there is no evidence of cardiac chamber or vascular enlargement. The pulmonary vasculature is within normal limits.

SEX

Female spayed

The trachea is normal in diameter and presents the anticipated course. The luminal outline of the trachea is smooth.

Generalized moderate thickening of the bronchial walls is appreciated. The lung parenchyma presents a generalized moderate unstructured reticular pattern, blurring the peripheral lung vessels. The volume of the right middle lung lobe is moderately decreased with generalized ground glass opacification of the parenchyma, the heart presents a midline shift to the right.

AGE

8 Years

The diaphragm is well delineated with even surface and the expected mild cranial bulging of the diaphragmatic cupola.

INTERPRETED BY

Sebastian Schaub, DVM
Dr. med. vet. DipECVDI

RADIOGRAPHIC DIAGNOSIS

- Broncho-interstitial lung pattern without signs of air-trapping
- Dystelectasis right middle lung lobe

HOSPITAL NAME

Four Corners
Veterinary Practice

INTERPRETATION OF THE FINDINGS & FURTHER RECOMMENDATIONS

The broncho-interstitial lung pattern in combination with the chronic cough are compatible with feline bronchial disease ('feline asthma'). Superinfection may deteriorate clinical signs - e.g. bacterial, Mycoplasma, viral, parasitic. The dystelectasis of the right middle lung lobe is commonly a sequela to bronchial mucous plugging and secondary resorption atelectasis, positional compression atelectasis is a potential as well.

REFERRING VET

Melina Maritato

INVOICE

52827

DATE

7-12-22



PATIENT

Paws Sroga

SPECIES

Feline

BREED

DSH

SEX

Female spayed

AGE

8 Years

INTERPRETED BY

Sebastian Schaub, DVM
Dr. med. vet. DipECVDI

HOSPITAL NAME

Four Corners
Veterinary Practice

REFERRING VET

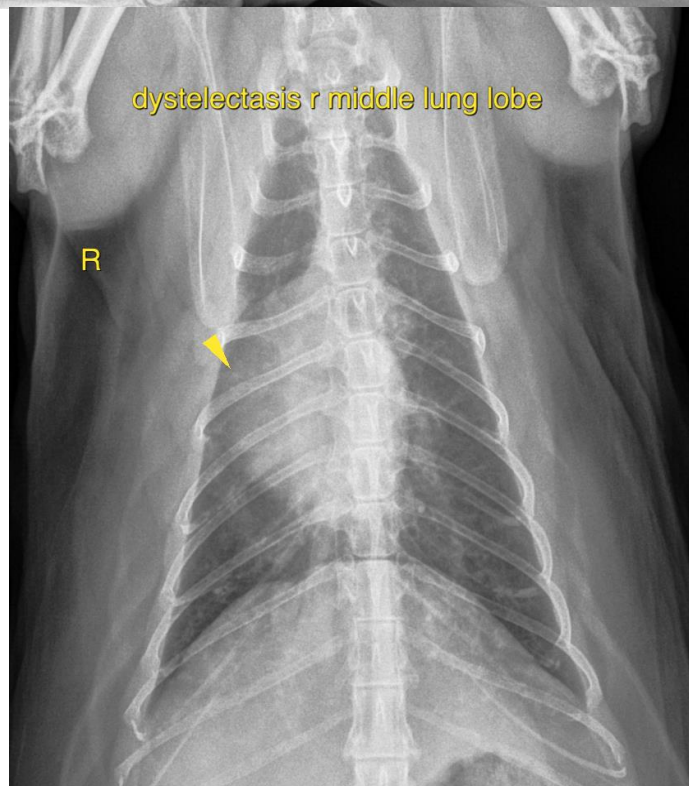
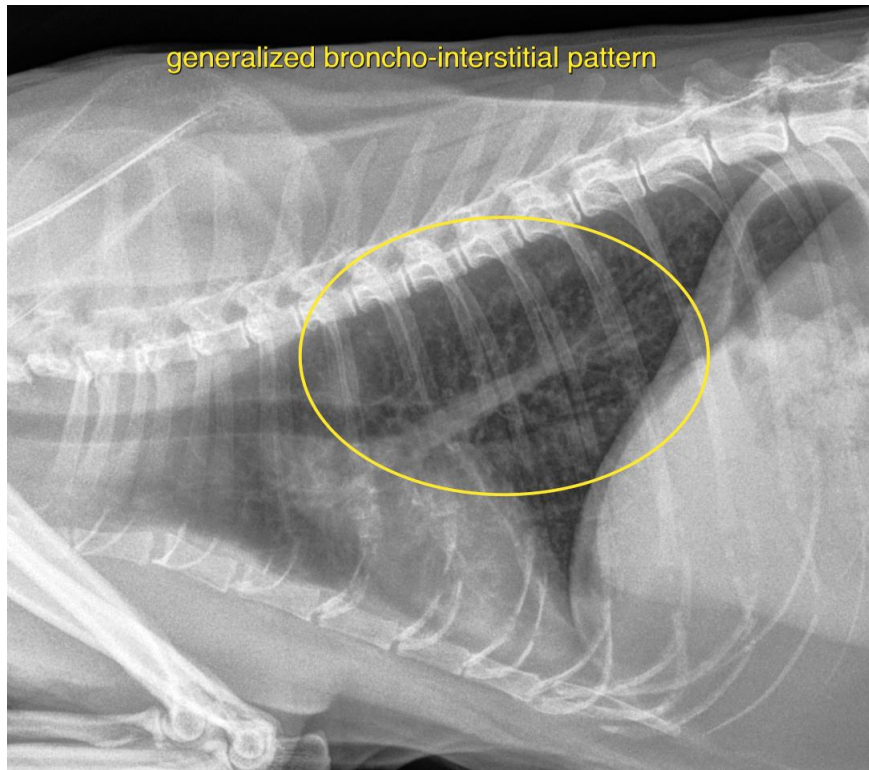
Melina Maritato

INVOICE

52827

DATE

7-12-22





PATIENT

Paws Sroga

The information and recommendations provided are based on the images presented by the referring veterinarian/sonographer. No evaluation can be communicated regarding pathology that was not visible in the image/video clips provided.

Thank you for this referral. If the clinical or image interpretation does not parallel your findings or if I can be of any further assistance please contact me.

SPECIES

Feline

Sebastian Schaub, Sebastian Schaub, DVM, Dr. med. vet. DipECVDI
sebast.schaub@gmail.com

BREED

DSH

SEX

Female spayed

AGE

8 Years

INTERPRETED BY

Sebastian Schaub, DVM
Dr. med. vet. DipECVDI

HOSPITAL NAME

Four Corners
Veterinary Practice

REFERRING VET

Melina Maritato

INVOICE

52827

DATE

7-12-22