



PATIENT PRESENTING CLINICAL SIGNS

PATIENT Bo Adams

SPECIES Canine

BREED Bluetick Hound

SEX MN

AGE 10 Years, 6 Months

Bo is here for further consultation about recently diagnosed mass effect within the region of the right caudal lung lobe. Xrays were taken due to history of hacking cough that occurs intermittently during the day over the last several weeks. Thoracic ultrasound performed June 17th did not reveal much about the mass effect due to the location (too much aerated lung between the thoracic wall and the mass). Mini chemistry panel performed 6/17 showed elevated liver values (ALT 146, SAP 537) and mildly elevated blood sugar (135). He is currently eating and drinking normally with no noted diarrhea or vomiting. Bo coughs at about 5am and then maybe when he is gets off of the floor but otherwise does not cough during the day. His energy is good. His sleeping position has changed, so that he tends to spread out instead of curling up in a ball. He is also sleeping on the floor instead of in his dog bed. Currently Bo is taking fenbendazole 2ml twice a day for 4 days on and then 3 days off, its to continue for 3-4 months. He is also taking high levels of antioxidants - a chew that contains things such as turkey tail, pine bark, turmeric, milk thistle etc. The cough is a dry cough for a few times and then ends in a terminal gag. He has been a healthy dog aside from having a sensitive stomach. Adopted about 10 years ago from Orville CA. He lived in CA for 4 years and then in OR for the past 6 years. No other travel history.

COMPUTED TOMOGRAPHY OF THE THORAX

A high resolution pre- and post-contrast CT study of the thorax is provided for review.

COMPUTED TOMOGRAPHIC FINDINGS

The bony and surrounding soft tissue structures are within normal limits.

The sternal, cranial mediastinal and tracheobronchial lymph nodes are small elongated with a normal short-to-long-axis-ratio is < 0.5, the attenuation and contrast enhancement pattern is uniform and considered within normal limits.

The cardiovascular structures including the pulmonary vasculature are within normal limits.

In the medial aspect of the right caudal lung lobe, an irregular marginated, soft tissue attenuating mass with mild amorphous mineralization is seen measuring 8.5 x 7.0 x 11.5 cm in size. The accompanying bronchi and vascular structured are deviated by the mass effect and compression atelectasis of the surrounding lung parenchyma is appreciated. Multifocal throughout the lung parenchyma, well-defined soft tissue attenuating nodular lesions of variable size are appreciated, measuring up to 10 mm in diameter. The volume of the accessory lung lobe is significantly decreased, and its contributing main bronchus is compressed by the pulmonary mass of the right caudal lung lobe.

Moderate thickening of the bronchial walls of the right middle lung lobe is noted.

Small incidental gas pockets are seen within the esophageal lumen, there is no evidence of abnormal dilation.

Protruding from the visceral surface of the body of the spleen, an irregular roundish, moderate contrast enhancing soft tissue mass is noted, measuring 6 cm in size. A splenic lymph node is moderately enlarged, rounded and presents a heterogeneous contrast enhancement pattern.

INTERPRETED BY

Sebastian Schaub, DVM
Dr. med. vet. DipECVDI

HOSPITAL NAME

Southern Oregon
Veterinary Specialty
Center

REFERRING VET

Kim Winters

INVOICE

52832

DATE

7-12-22



PATIENT

Bo Adams

SPECIES

Canine

BREED

Bluetick Hound

SEX

MN

AGE

10 Years, 6 Months

INTERPRETED BY

Sebastian Schaub, DVM
Dr. med. vet. DipECVCI

HOSPITAL NAME

Southern Oregon
Veterinary Specialty
Center

REFERRING VET

Kim Winters

INVOICE

52832

DATE

7-12-22

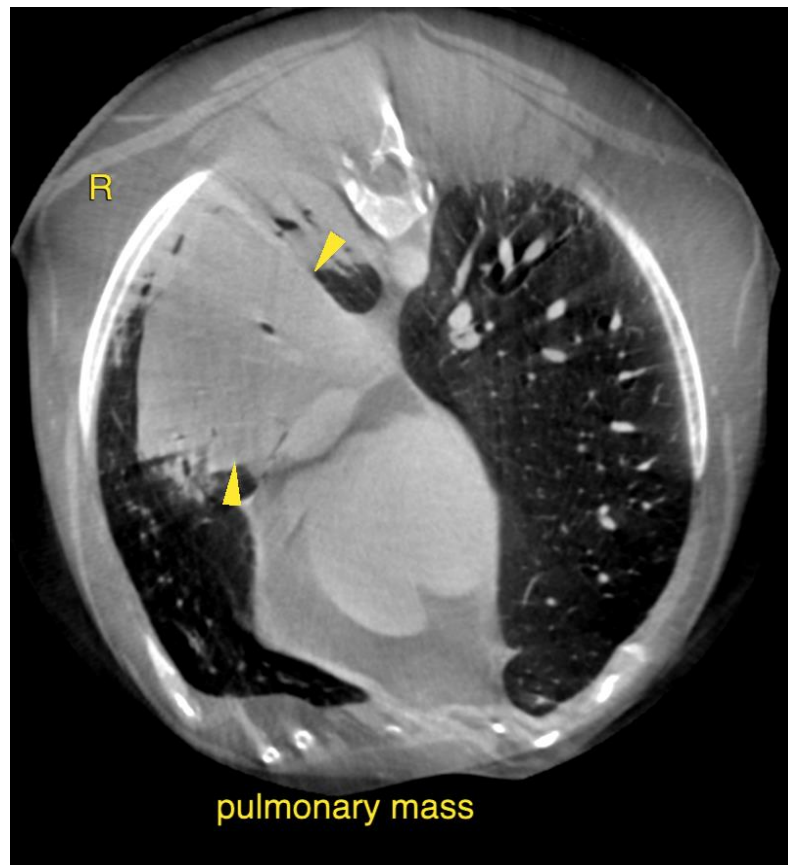
COMPUTED TOMOGRAPHIC DIAGNOSIS

- Pulmonary mass right caudal lung lobe
- Structured nodular interstitial lung pattern and thickening of the bronchial walls right middle lung lobe
- Splenic soft tissue mass
- Lymphadenopathy splenic lymph node
- Resorption atelectasis accessory lung lobe

INTERPRETATION OF THE FINDINGS & FURTHER RECOMMENDATIONS

The CT study is consistent with primary pulmonary neoplasia – carcinoma is most common – and secondary pulmonary and bronchial metastatic spread. Ultrasound guided FNA sampling can be used as advanced minimally invasive diagnostic tool.

The splenic mass might present a second entity (e.g. hemangiosarcoma, round cell tumor) or metastatic disease of the pulmonary mass. The odds for metastatic spread to a splenic lymph node are high.





PATIENT

Bo Adams

SPECIES

Canine

BREED

Bluetick Hound

SEX

MN

AGE

10 Years, 6 Months

INTERPRETED BY

Sebastian Schaub, DVM
Dr. med. vet. DipECVDI

HOSPITAL NAME

Southern Oregon
Veterinary Specialty
Center

REFERRING VET

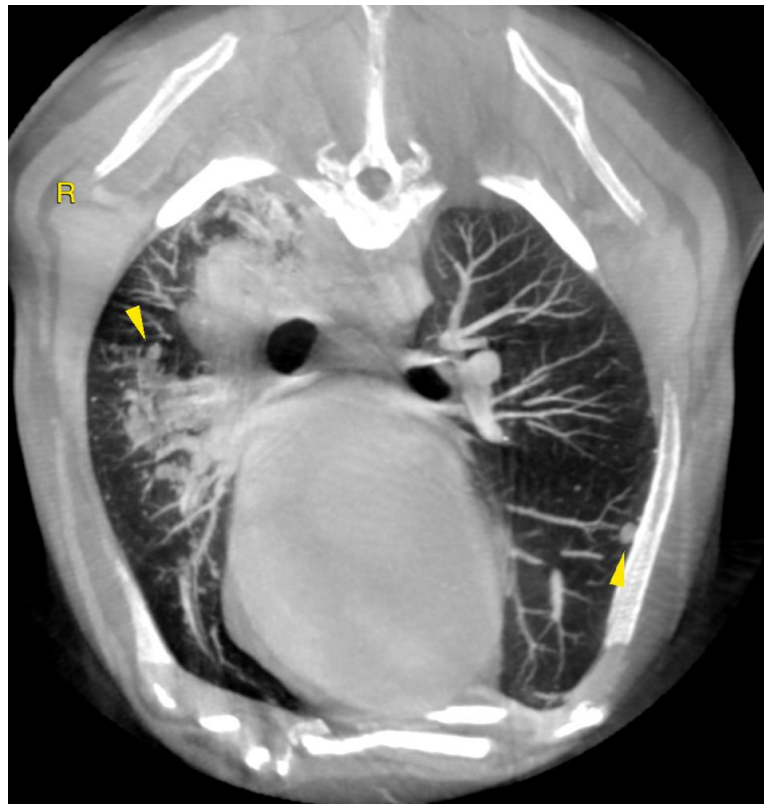
Kim Winters

INVOICE

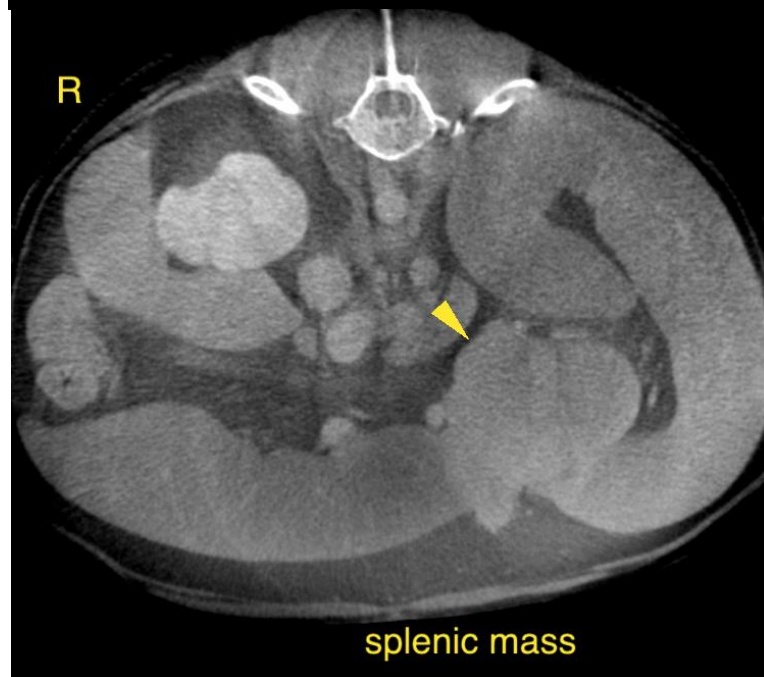
52832

DATE

7-12-22



nodular lung pattern



splenic mass



PATIENT

Bo Adams

SPECIES

Canine

BREED

Bluetick Hound

SEX

MN

AGE

10 Years, 6 Months

INTERPRETED BY

Sebastian Schaub, DVM
Dr. med. vet. DipECVDI

HOSPITAL NAME

Southern Oregon
Veterinary Specialty
Center

REFERRING VET

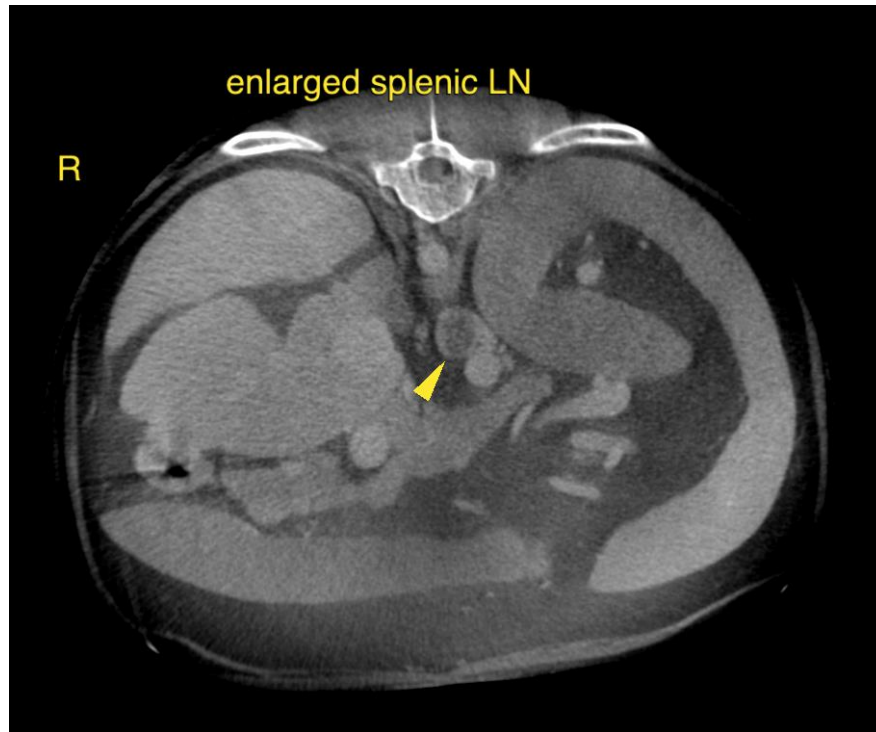
Kim Winters

INVOICE

52832

DATE

7-12-22



The information and recommendations provided are based on the images presented by the referring veterinarian/sonographer. No evaluation can be communicated regarding pathology that was not visible in the image/video clips provided.

Thank you for this referral. If the clinical or image interpretation does not parallel your findings or if I can be of any further assistance please contact me.

Sebastian Schaub, Sebastian Schaub, DVM, Dr. med. vet. DipECVDI
sebast.schaub@gmail.com