



PATIENT PRESENTING CLINICAL SIGNS

Teddy Sharpe Limping lhl r/o orthopedic injury vs. Soft tissue injury vs. Fracture vs. Other intact male r mpl
Abnormal PE/Chem/CBC/UA Results: unremarkable

SPECIES RADIOGRAPHIC STUDY OF THE STIFLE JOINTS

Canine Radiographs of the stifle joints in two orthogonal imaging planes are provided for review. Radiographs are provided in JPEG file formation.

RADIOGRAPHIC FINDINGS

BREED
Pomeranian Both stifle joints have smooth osseous margins of the periarticular bones and present no sign of intracapsular soft tissue swelling. In the craniocaudal view, the patella of the right stifle joint is in a relative medial position, superimposed on the medial femoral condyle.

RADIOGRAPHIC DIAGNOSIS

- SEX**
M
- Right sided medial patellar luxation
 - Normal left stifle joint

INTERPRETATION OF THE FINDINGS & FURTHER RECOMMENDATIONS

AGE
11 Months The radiographic study of the left stifle joint presents without abnormalities, explaining the left hind limb lameness. Rule out left sided patellar luxation via the clinical examination. The radiographic study presents no evidence of fracture.

INTERPRETED BY

Sebastian Schaub, DVM
Dr. med. vet. DipECVDI

TECHNICAL COMMENTS

Gloved hands are seen in the primary beam, please consider radiation safety guidelines.

HOSPITAL NAME

My Pet Mobile Vet

REFERRING VET

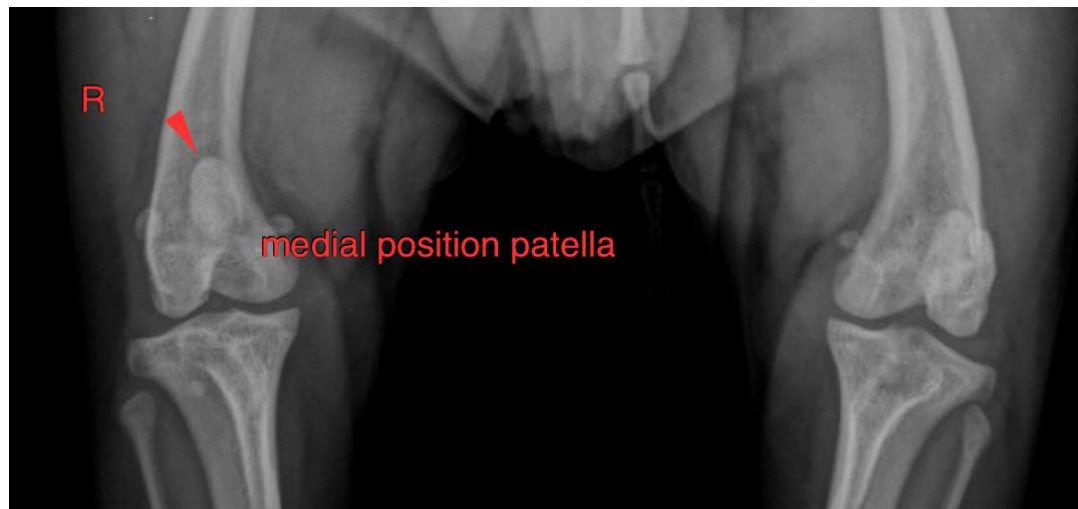
Dr. Claudia Lau

INVOICE

59269

DATE

7-11-23





PATIENT

Teddy Sharpe

The information and recommendations provided are based on the images presented by the referring veterinarian/sonographer. No evaluation can be communicated regarding pathology that was not visible in the image/video clips provided.

Thank you for this referral. If the clinical or image interpretation does not parallel your findings or if I can be of any further assistance please contact me.

SPECIES

Canine

Sebastian Schaub, Sebastian Schaub, DVM, Dr. med. vet. DipECVDI
info@sonopath.com

BREED

Pomeranian

SEX

M

AGE

11 Months

INTERPRETED BY

Sebastian Schaub, DVM
Dr. med. vet. DipECVDI

HOSPITAL NAME

My Pet Mobile Vet

REFERRING VET

Dr. Claudia Lau

INVOICE

59269

DATE

7-11-23