



PATIENT PRESENTING CLINICAL SIGNS

Mabel Vico LIMPING
Abnormal PE/Chem/CBC/UA Results: CV/Respiratory: Normal heart rate and rhythm, no murmur, pulses strong and synchronous, normal bronchovesicular sounds. EENT: Clear OU and AU. No nasal discharge. No cough on tracheal palpation. Oral cavity: Mild dental tartar Musculoskeletal: BCS = 6/9. Ambulatory x 4. LH: Firm "bump" at dorsal aspect of distal metatarsal region. Uro/Perineum: No significant lesions Abd/GI: Soft, non-painful. No masses or fluid wave palpated Lymph Nodes: No peripheral lymphadenopathy Neurological: Alert and appropriate. No significant abnormalities Skin: Good hair coat. No ectoparasites seen Mentation: BAR

BREED RADIOGRAPHIC STUDY OF THE LEFT HIND PAW

DSH Radiographs of the left hind paw in two orthogonal imaging planes are provided for review.

RADIOGRAPHIC FINDINGS

SEX
SF The distal third of the diaphysis of the third metatarsal bone of the left hind paw presents a well-defined, transverse fracture line with an isolated cortical fragment at the plantar aspect. The distal fragment of the third metatarsal bone is mildly deviated dorsally and proximally. A mild to moderate soft tissue swelling is appreciated dorsal to the metatarsal bones.

AGE RADIOGRAPHIC DIAGNOSIS

7 Years, 9 Months

- Acute traumatic transverse fracture third metatarsal bone left hind paw with an isolated plantar cortical fragment

INTERPRETED BY

Sebastian Schaub, DVM
Dr. med. vet. DipECVDI

INTERPRETATION OF THE FINDINGS & FURTHER RECOMMENDATIONS

The fractured third metatarsal bone is a plausible explanation for the left hind limb lameness.

HOSPITAL NAME

DPC Veterinary
Hospital

REFERRING VET

Dr. Rivera

INVOICE

59289

DATE

7-11-23



PATIENT

Mabel Vico

SPECIES

Feline

BREED

DSH

SEX

SF

AGE

7 Years, 9 Months

INTERPRETED BY

Sebastian Schaub, DVM
Dr. med. vet. DipECVDI

HOSPITAL NAME

DPC Veterinary
Hospital

REFERRING VET

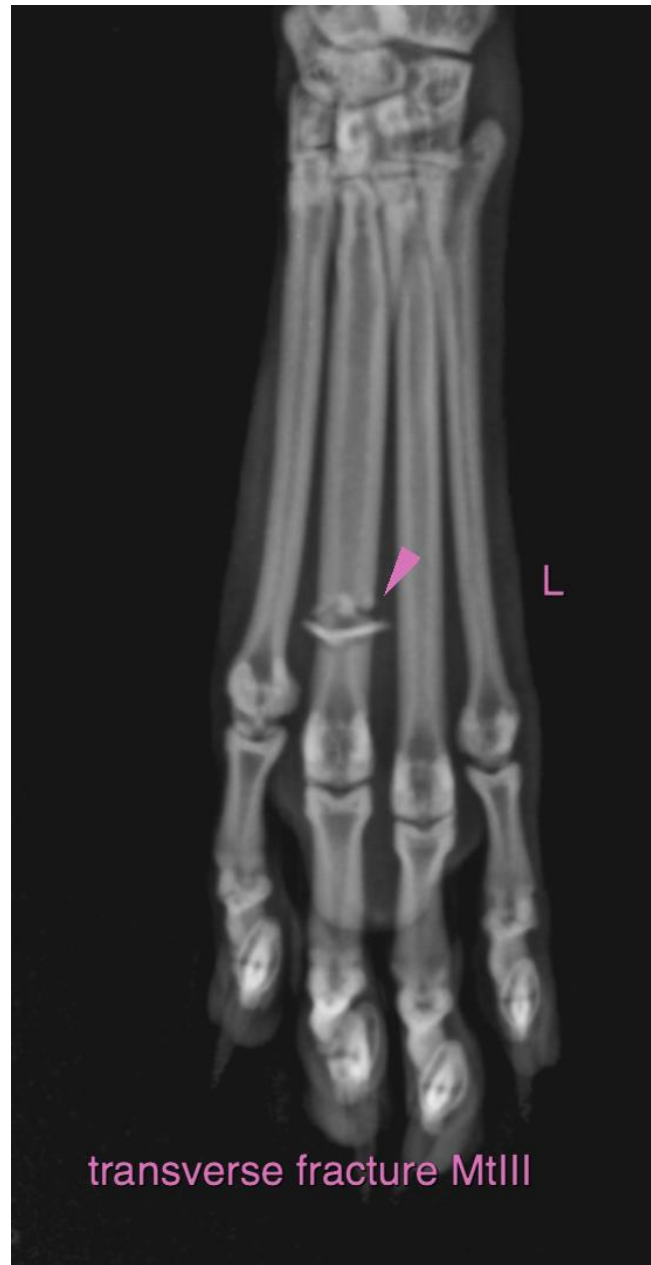Dr. Rivera

INVOICE

59289

DATE

7-11-23





PATIENT

Mabel Vico

SPECIES

Feline

BREED

DSH

SEX

SF

AGE

7 Years, 9 Months

INTERPRETED BY

Sebastian Schaub, DVM
Dr. med. vet. DipECVDI

HOSPITAL NAME

DPC Veterinary
Hospital

REFERRING VET

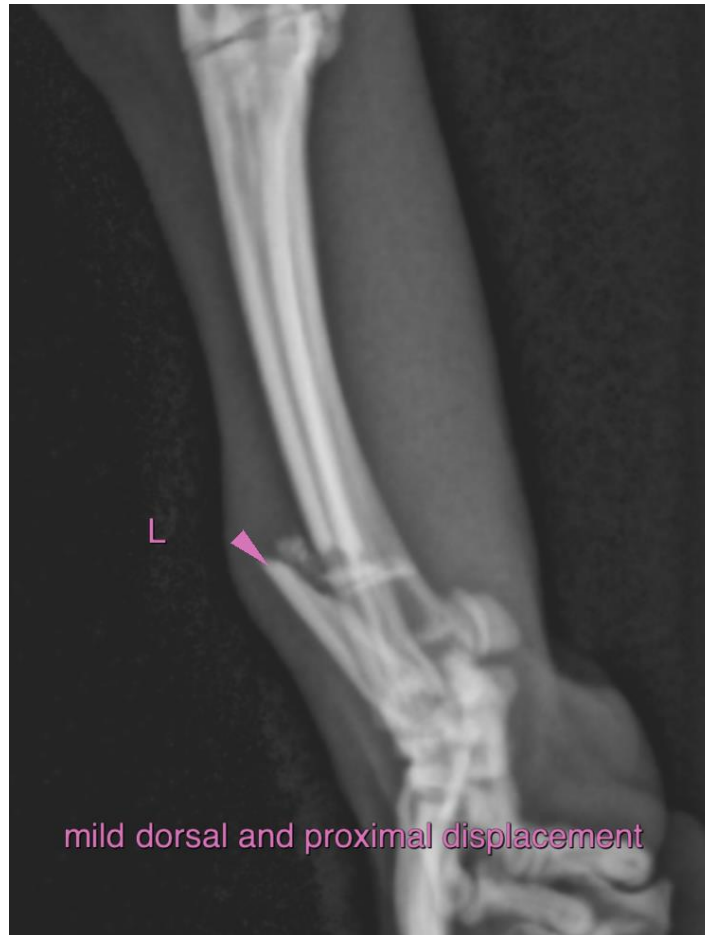
Dr. Rivera

INVOICE

59289

DATE

7-11-23



The information and recommendations provided are based on the images presented by the referring veterinarian/sonographer. No evaluation can be communicated regarding pathology that was not visible in the image/video clips provided.

Thank you for this referral. If the clinical or image interpretation does not parallel your findings or if I can be of any further assistance please contact me.

Sebastian Schaub, Sebastian Schaub, DVM, Dr. med. vet. DipECVDI
info@sonopath.com