



PATIENT PRESENTING CLINICAL SIGNS

Addie Drinkwater Stiff gait in hind limbs. Decreased ROM both coxofemoral joints.

COMPUTED TOMOGRAPHY OF THE PELVIS

SPECIES A high resolution plain CT study of the pelvis is provided for review.

Canine **COMPUTED TOMOGRAPHIC FINDINGS**

The pictured parts of the caudal lumbar spine/lumbosacral junction present no abnormalities.

BREED The osseous and surrounding soft tissue structures of the pelvis are within normal limits. Both coxofemoral joints present mild osteophyte new bone formation.

Golden Retriever

COMPUTED TOMOGRAPHIC DIAGNOSIS

- SEX**
- Mild degenerative osteoarthritis coxofemoral joints bilaterally
 - Normal lumbosacral junction

FS

INTERPRETATION OF THE FINDINGS & FURTHER RECOMMENDATIONS

AGE The mild degenerative joint disease of the coxofemoral joints is likely a sequela to mild hip dysplasia and can be a source for the described clinical signs.

7 Years

INTERPRETED BY

Sebastian Schaub, DVM
Dr. med. vet. DipECVDI

HOSPITAL NAME

Paws and Claws
Urgent Care

REFERRING VET

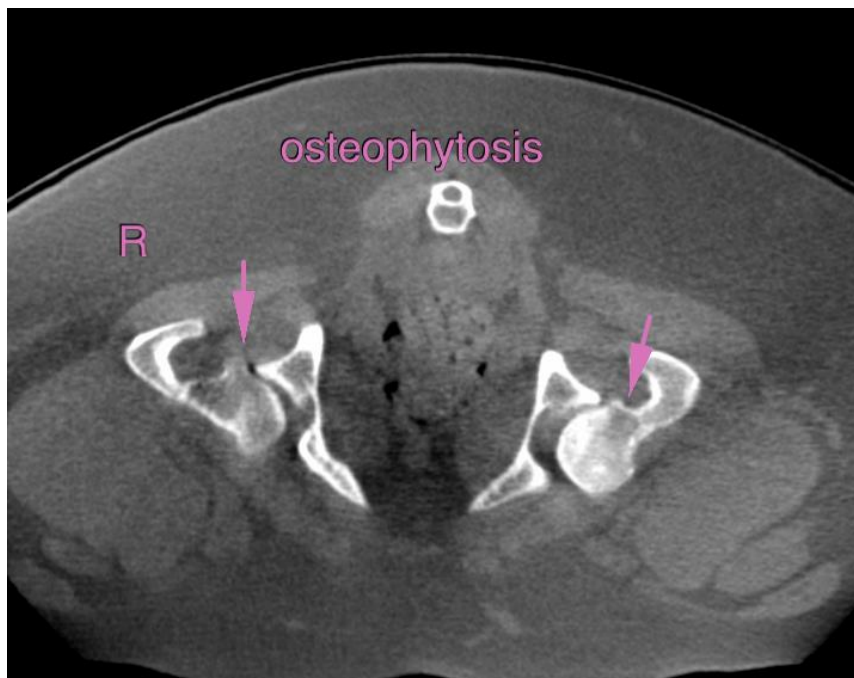
Shakira Jameson

INVOICE

59290

DATE

7-11-23





PATIENT

Addie Drinkwater

The information and recommendations provided are based on the images presented by the referring veterinarian/sonographer. No evaluation can be communicated regarding pathology that was not visible in the image/video clips provided.

SPECIES

Canine

Thank you for this referral. If the clinical or image interpretation does not parallel your findings or if I can be of any further assistance please contact me.

BREED

Golden Retriever

Sebastian Schaub, Sebastian Schaub, DVM, Dr. med. vet. DipECVDI
info@sonopath.com

SEX

FS

AGE

7 Years

INTERPRETED BY

Sebastian Schaub, DVM
Dr. med. vet. DipECVDI

HOSPITAL NAME

Paws and Claws
Urgent Care

REFERRING VET

Shakira Jameson

INVOICE

59290

DATE

7-11-23