



PATIENT

Stella Neely

PRESENTING CLINICAL SIGNS

inappetence for 3 days
Abnormal PE/Chem/CBC/UA Results: unremarkable

SPECIES

Canine

RADIOGRAPHIC STUDY OF THE ABDOMEN

Radiographs of the abdomen in three imaging planes are provided for review.

BREED

Bulldog, French

RADIOGRAPHIC FINDINGS

T12 has a wedge shaped conformation and the respective vertebral endplates present mild spondylosis formation.

No abnormalities of the extraabdominal soft tissues are noted. The abdominal wall is smooth and thin.

SEX

Female

The serosal detail is maintained throughout the peritoneal and retroperitoneal space.

The liver is appropriate in position, size and presents uniform opacity.

AGE

2 Years

The splenic head is in the anticipated position and within normal limits for size and opacity. The splenic body and tail are considered normal for position, size, shape and opacity.

Both kidneys are seen and present with normal size, shape, delineation and opacity. The urinary bladder is in its anticipated position. No radiopaque calculi are noted throughout the upper and lower urinary tract.

INTERPRETED BY

Sebastian Schaub, DVM
Dr. med. vet. DipECVDI

The stomach is in its anticipated position and is empty.

In the right cranial abdomen, a mild gas distended small intestinal loop is noted.

The colon is seen in the expected position and presents with appropriate content.

HOSPITAL NAME

St. Catherine's Animal
Hospital

RADIOGRAPHIC DIAGNOSIS

- Segmental mild dilation of a small intestinal loop
- Empty stomach
- Hemivertebra T12

REFERRING VET

Dr. Boctor

INTERPRETATION OF THE FINDINGS & FURTHER RECOMMENDATIONS

The segmental dilation of a small intestinal loop is not specific and can indicate segmental atonic jejunal segment – possibly due to (gastro)enteritis. There is no evidence of radiopaque foreign material. If clinical signs are refractory to therapy, recommend follow up radiographs or a complete abdominal ultrasound examination.

INVOICE

52797

DATE

7-11-22



PATIENT

Stella Neely

SPECIES

Canine

BREED

Bulldog, French

SEX

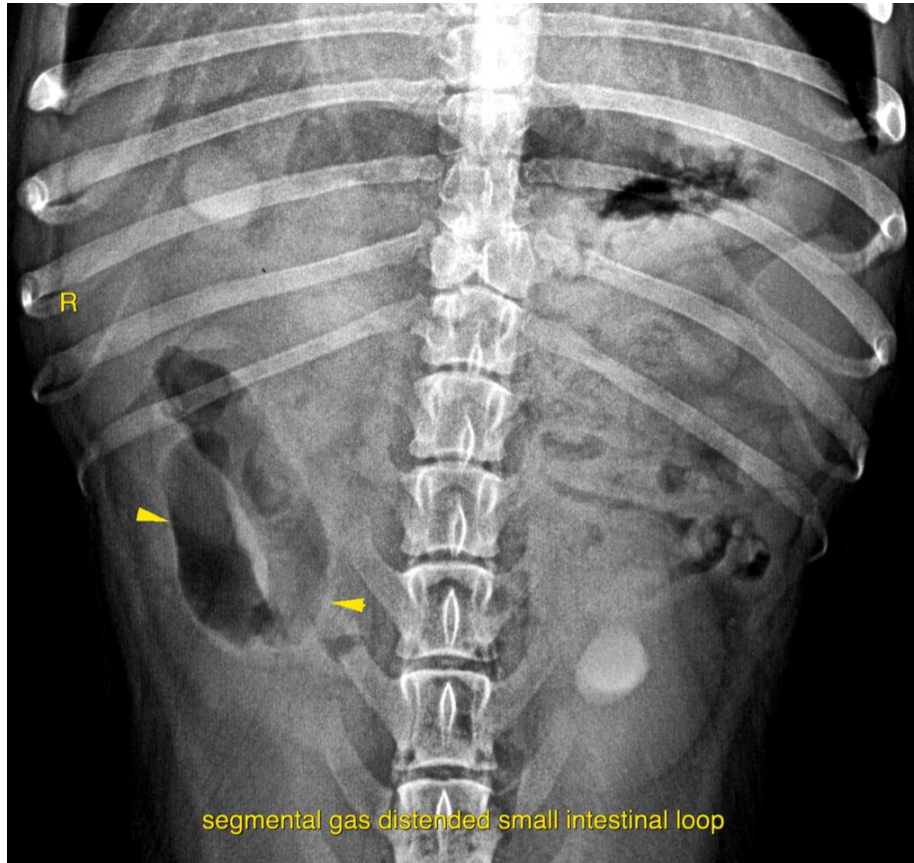
Female

AGE

2 Years

INTERPRETED BY

Sebastian Schaub, DVM
Dr. med. vet. DipECVDI



HOSPITAL NAME

St. Catherine's Animal
Hospital

REFERRING VET

Dr. Boctor

INVOICE

52797

DATE

7-11-22

The information and recommendations provided are based on the images presented by the referring veterinarian/sonographer. No evaluation can be communicated regarding pathology that was not visible in the image/video clips provided.

Thank you for this referral. If the clinical or image interpretation does not parallel your findings or if I can be of any further assistance please contact me.

Sebastian Schaub, Sebastian Schaub, DVM, Dr. med. vet. DipECVDI
sebast.schaub@gmail.com