



**PATIENT PRESENTING CLINICAL SIGNS**

Binx Tirri Hx of chronic obstipation, had subtotal colectomy 12/2021. Obstipated again 7/2022. Appears to have narrow pelvis canal; potential trauma to pelvic region prior to adoption.

**SPECIES COMPUTED TOMOGRAPHY OF THE CAUDAL LUMBAR SPINE/PELVIS**

Feline A pre- and post-contrast CT study of the skull and abdomen and a post-contrast CT study of the thorax are provided for review.

**COMPUTED TOMOGRAPHIC FINDINGS**

**BREED** The vertebral endplates L7/S1 present mild spondylosis formation.

Domestic Shorthair Mild medial deviation of the right hemipelvis is appreciated, causing mild to moderate narrowing of the pelvis canal - measuring 2.1 cm in width.

**SEX** The right ischial bone, caudal to the acetabulum and the right tabula ossis ischii present evidence of healed transverse fracture with mild smooth callus formation.

Male The rectum contains a small amount of hyperattenuating fecal material. Focal narrowing of the rectum is appreciated – suspect level anastomosis between ileum and rectum.

**AGE** The distal segment of the right femur, included within the field of view, presents evidence of a distal diaphyseal femoral fracture with smooth callus formation.

2.7 Years

**INTERPRETED BY COMPUTED TOMOGRAPHIC DIAGNOSIS**

Sebastian Schaub, DVM  
Dr. med. vet. DipECVDI

- Mild stenosis of the pelvic canal, due to fracture of the right hemipelvis – the fracture lines are in the remodeling phase
- Small amount of hyperattenuating fecal material in the rectum
- Right sided healed distal femoral fracture
- History of subtotal colectomy

**HOSPITAL NAME**

Westwood Regional  
Veterinary Hospital

**REFERRING VET**

George Cattiny, DVM

**INTERPRETATION OF THE FINDINGS & FURTHER RECOMMENDATIONS**

The stenosis of the pelvic canal caused by the medial deviation of the right is only mild. At this point treatment with Cisapride to support peristalsis might be beneficial. For long term treatment, dietary management (e.g. soluble fibers and psyllium) with or without oral lactulose may help to support digestive transit and soften the stool. Increase water intake may be beneficial as well.

**INVOICE**

52792

**DATE**

7-11-22



**PATIENT**

Binx Tirri

**SPECIES**

Feline

**BREED**

Domestic Shorthair

**SEX**

Male

**AGE**

2.7 Years

**INTERPRETED BY**

Sebastian Schaub, DVM  
Dr. med. vet. DipECVDI

**HOSPITAL NAME**

Westwood Regional  
Veterinary Hospital

**REFERRING VET**

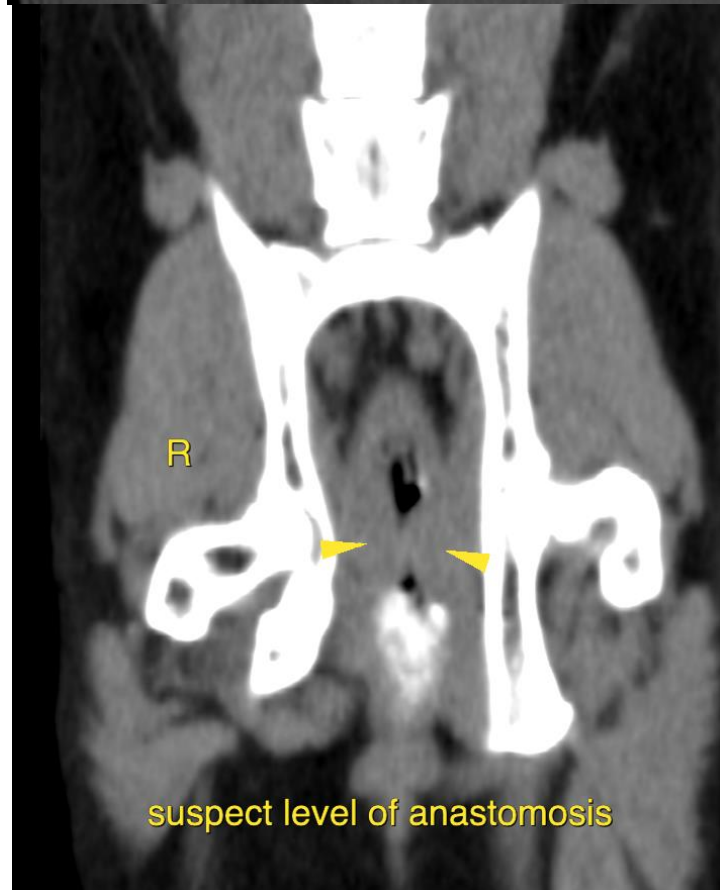
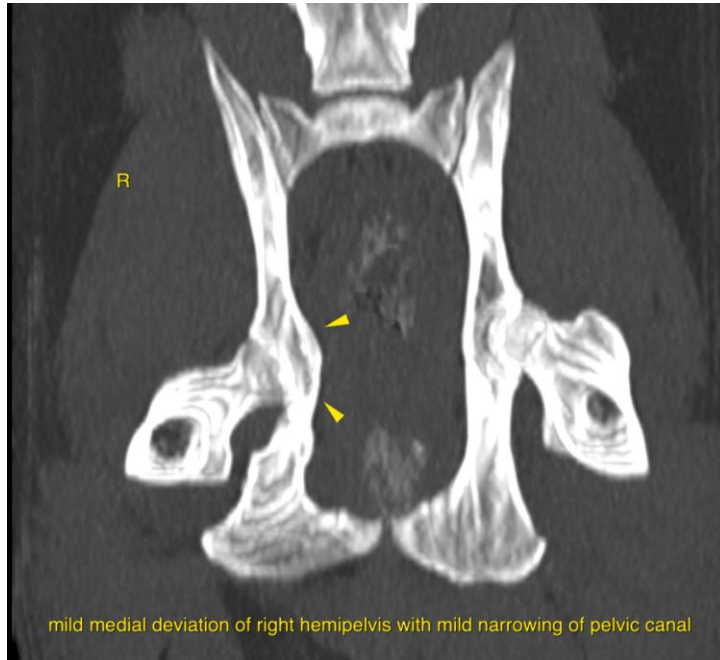
George Cattiny, DVM

**INVOICE**

52792

**DATE**

7-11-22





**PATIENT**

Binx Tirri

**SPECIES**

Feline

**BREED**

Domestic Shorthair

**SEX**

Male

**AGE**

2.7 Years

**INTERPRETED BY**

Sebastian Schaub, DVM  
Dr. med. vet. DipECVDI

**HOSPITAL NAME**

Westwood Regional  
Veterinary Hospital

**REFERRING VET**

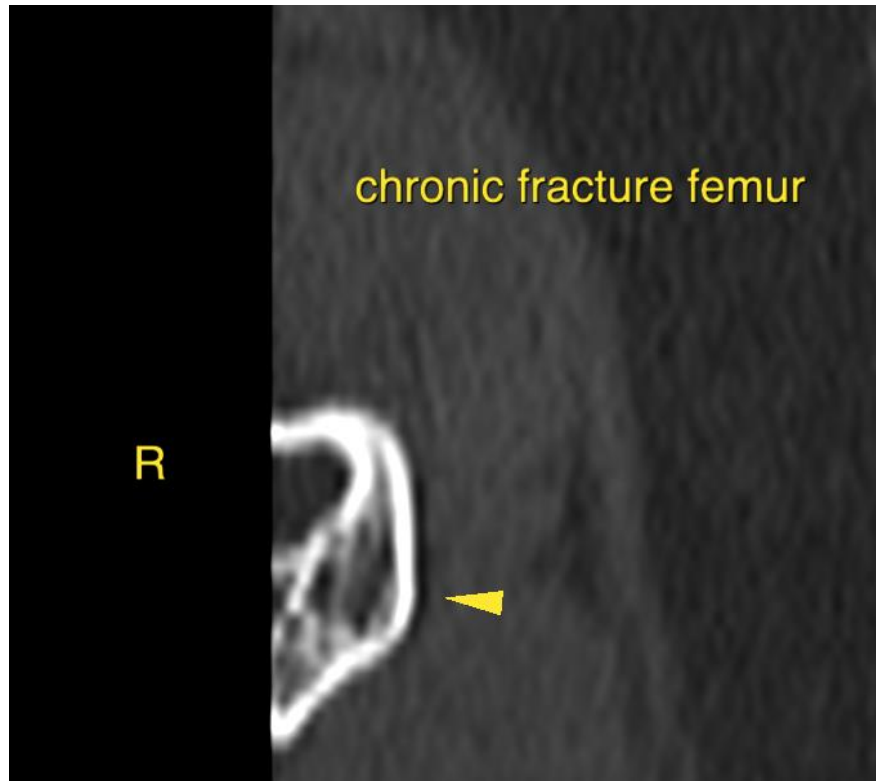
George Cattiny, DVM

**INVOICE**

52792

**DATE**

7-11-22



The information and recommendations provided are based on the images presented by the referring veterinarian/sonographer. No evaluation can be communicated regarding pathology that was not visible in the image/video clips provided.

Thank you for this referral. If the clinical or image interpretation does not parallel your findings or if I can be of any further assistance please contact me.

**Sebastian Schaub**, Sebastian Schaub, DVM, Dr. med. vet. DipECVDI  
sebast.schaub@gmail.com