



PATIENT PRESENTING CLINICAL SIGNS

Gabriella Nadkarni History: 13 y 1 m toy poodle presented for appearing painful somewhere. Ms in the room does not know much information as it is her husbands dog. Pet had an episode with mr daughter when she yelped in pain.

SPECIES Abnormal PE/Chem/CBC/UA Results: Physical Examination Key -- (N= Normal, A= Abnormal)
Canine Hydration: Appropriately hydrated Mentation: BAR EENT: No nasal discharge; nuclear sclerosis OU; clean no debris AU; N Oral Cavity: heavy dental tartar present, missing many teeth Lymph Nodes: Symmetrical, no changes in size, shape, consistency Skin: Good hair coat, FLEAS. Salivary staining all 4 paws. Few dermal growths < 1 cm lobulated on body. CV/Respiratory: No murmur or crackles/wheezing auscultated. Synchronous pulses, normal rate. Normal bronchovesicular sounds. Abd/GI: Mildly tense non painful abdomen, no palpable organomegaly or abnormalities Uro/Perineum: N Musculoskeletal: Ambulatory x4, no lameness noted. Crepitus caudal lumbar spine - P not reactive. BCS 5/9
BREED Toy Poodle
SEX SF
AGE 13 Years

RADIOGRAPHIC STUDY OF THE LUMBAR SPINE

Radiographs of the lumbar spine in two orthogonal imaging planes are provided for review.

RADIOGRAPHIC FINDINGS

The intervertebral disc space L4/L5 is narrowed.

The remainder of the osseous and soft tissue structures of the lumbar spine are within normal limits.

INTERPRETED BY

RADIOGRAPHIC DIAGNOSIS

Sebastian Schaub, DVM
 Dr. med. vet. DipECVDI

- Discopathy L4/L5

HOSPITAL NAME INTERPRETATION OF THE FINDINGS & FURTHER RECOMMENDATIONS

DPC Veterinary Hospital

The narrowed intervertebral disc space L4/L5 indicates discopathy that might or may not be associated with compressive myelopathy.

REFERRING VET

Dr. White

INVOICE

59265

DATE

7-10-23



PATIENT

Gabriella Nadkarni

SPECIES

Canine

BREED

Toy Poodle

SEX

SF

AGE

13 Years

INTERPRETED BY

Sebastian Schaub, DVM
Dr. med. vet. DipECVDI

HOSPITAL NAME

DPC Veterinary
Hospital

REFERRING VET

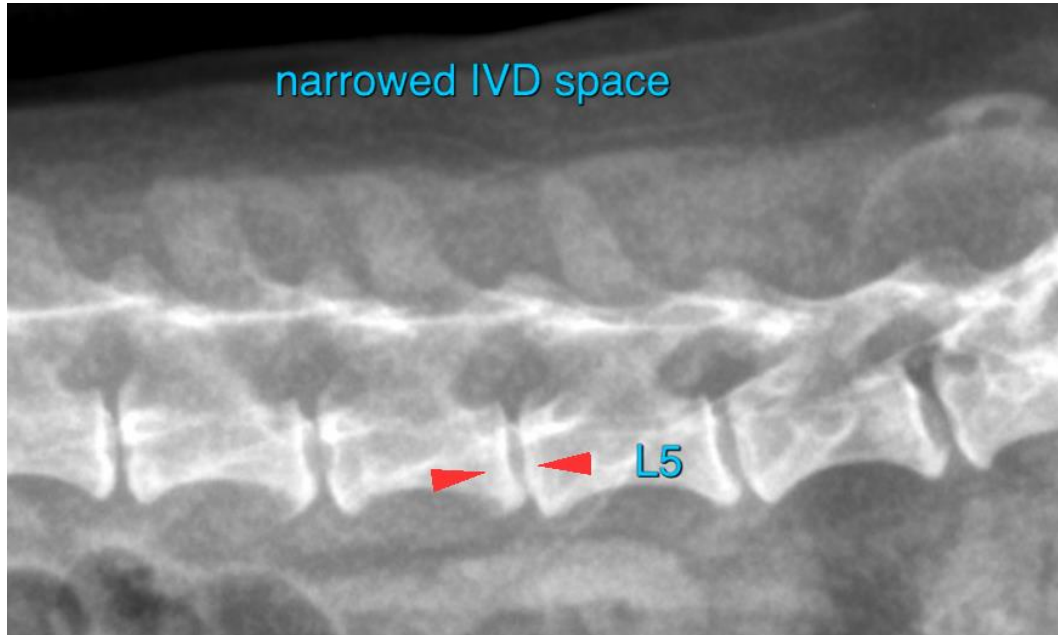
Dr. White

INVOICE

59265

DATE

7-10-23



The information and recommendations provided are based on the images presented by the referring veterinarian/sonographer. No evaluation can be communicated regarding pathology that was not visible in the image/video clips provided.

Thank you for this referral. If the clinical or image interpretation does not parallel your findings or if I can be of any further assistance please contact me.

Sebastian Schaub, Sebastian Schaub, DVM, Dr. med. vet. DipECVDI
info@sonopath.com